Journal Pre-proof



THE DIFFERENTIATION OF THE COMPETITIVE ATHLETE WITH PHYSIOLOGIC CARDIAC REMODELING FROM THE ATHLETE WITH CARDIOMYOPATHY

ROBERT J. HENNING M.D., FACP, FCCP, FACC, FAHA

PII: S0146-2806(24)00112-9
DOI: https://doi.org/10.1016/j.cpcardiol.2024.102473
Reference: YMCD 102473

To appear in: *Current Problems in Cardiology*

Please cite this article as: ROBERT J. HENNING M.D., FACP, FCCP, FACC, FAHA , THE DIFFERENTIATION OF THE COMPETITIVE ATHLETE WITH PHYSIOLOGIC CARDIAC REMODELING FROM THE ATHLETE WITH CARDIOMYOPATHY, *Current Problems in Cardiology* (2024), doi: https://doi.org/10.1016/j.cpcardiol.2024.102473

This is a PDF file of an article that has undergone enhancements after acceptance, such as the addition of a cover page and metadata, and formatting for readability, but it is not yet the definitive version of record. This version will undergo additional copyediting, typesetting and review before it is published in its final form, but we are providing this version to give early visibility of the article. Please note that, during the production process, errors may be discovered which could affect the content, and all legal disclaimers that apply to the journal pertain.

Published by Elsevier Inc.

Journal Pre-proof

THE DIFFERENTIATION OF THE COMPETITIVE ATHLETE WITH PHYSIOLOGIC CARDIAC REMODELING FROM THE ATHLETE WITH CARDIOMYOPATHY

Running Title: Athlete's Heart versus Athlete Cardiomyopathy

ROBERT J. HENNING, M.D., FACP, FCCP, FACC, FAHA

UNIVERSITY OF SOUTH FLORIDA

Journal Pre-proof

ADDRESS CORRESPONDENCE TO ROBERT J. HENNING, M.D., UNIVERSITY OF SOUTH FLORIDA 13201 BRUCE B. DOWNS BLVD.TAMPA, FLORIDA 33612-3805, email: roberthenningmd@gmail.com

FINANCIAL & COMPETING INTERESTS DISCLOSURE: Work in the cardiovascular research laboratory of the Author is supported by a grant from the Cardiomyopathy Foundation. The author has no other relevant affiliations and no financial involvement with any organization or entity with a financial interest in or financial conflict with the subject matter or materials discussed in this article.

ABSTRACT

There are currently 5 million active high school, collegiate, professional, and master athletes in the United States. Regular intense exercise by these athletes can promote structural, electrical and functional remodeling of the heart, which is termed the "athlete's heart." In addition, regular intense exercise can lead to pathological adaptions that promote or worsen cardiac disease. Many of the athletes in the United States seek medical care. Consequently, physicians must be aware of the normal cardiac anatomy and physiology of the athlete, the differentiation of the normal athlete heart from the athlete with cardiomyopathy, and the contemporary care of the athlete with a cardiomyopathy.

In athletes with persistent cardiovascular symptoms, investigations should include a detailed history and physical examination, an ECG, a transthoracic echocardiogram, and in athletes in whom the diagnosis is uncertain, a maximal exercise stress test or a continuous ECG recording, and cardiac magnetic resonance imaging or a cardiac computed tomography angiography when definition of the coronary anatomy or characterization of the aorta and the aortic great vessels is indicated. This article discusses the differentiation of the normal athlete with physiologic cardiac remodeling from the athlete with hypertrophic, dilated or arrhythmogenic ventricular cardiomyopathy (ACM). The ECG changes in trained athletes that are considered normal, borderline, or abnormal are listed. In addition, the normal echocardiographic measurements for athletes who consistently participate in endurance, power, combined or heterogeneous sports are enumerated and discussed. Algorithms are listed that are useful in the diagnosis of trained athletes with borderline or abnormal echocardiographic measurements suggestive of cardiomyopathies along with the major and minor criteria for the diagnosis of ACM in athletes. Thereafter, the treatment of athletes with hypertrophic, dilated, and arrhythmogenic right ventricular cardiomyopathies are reviewed. The distinction between physiologic changes and pathologic changes in the hearts of athletes has important therapeutic and prognostic implications. Failure by the physician to correctly diagnose an athlete with hypertrophic cardiomyopathy, dilated cardiomyopathy, or ACM, can lead to the sudden cardiac arrest and death of the athlete during training or sports competition. In contrast, an incorrect diagnosis by a physician of cardiac pathology in a normal athlete can lead to an unnecessary restriction of athlete training and competition with resultant significant emotional, psychological, financial, and long-term health consequences in the athlete.

Journal Pre-proof

INTRODUCTION:

There are currently 5 million active high school, collegiate, professional, and master athletes in the United States. When the athletes in each of these groups seeks medical care, physicians must be aware of the normal cardiac anatomy and physiology of the athlete, the differentiation of the normal athletic heart from the athlete with cardiomyopathy, and the contemporary care of the trained athlete with physiologic heart remodeling and the athlete with cardiomyopathy.

Females	**22**	**32**

Among competitive athletes, regular intense exercise promotes structural, electrical and functional remodeling of the heart, which is termed the "athlete's heart" [1]. Important factors that determine this cardiac remodeling are the age, sex, ethnicity, diet, and the presence of comorbidities, the type of exercise, and the frequency and the total duration of exercise. Regular intense exercise can also lead to pathological adaptions that can promote or worsen cardiac disease such as atrial dilation/atrial fibrillation, ventricular dilation, and rhythm disorders. All physicians must recognize that the cardiac remodeling that can occur due to regular intense exercise is often difficult to distinguish from the remodeling due to cardiac pathology. Furthermore, the differentiation between the normal athlete heart and the athlete with cardiac pathology is further complicated by the use by athletes of anabolic steroids, stimulants, and red blood cell–boosting agents [1].

The distinction between physiologic changes and pathologic changes in the hearts of athletes has important prognostic and therapeutic implications. Physicians who examine athletes must exclude hypertrophic cardiomyopathy (HCM), dilated cardiomyopathy (DCM), arrhythmogenic right ventricular cardiomyopathy (ACM), and in the athlete who is ≥35 years of age the presence of atherosclerotic obstructive coronary artery disease. Failure by the physician to correctly diagnose cardiac pathology in an athlete can lead to the sudden cardiac arrest and death in the athlete. Cardiac arrest is more frequent in male athletes than in female athletes and is significantly more common in Black athletes than white athletes [2, 3]. TABLE 1 lists the demographics of sudden death in young athletes and is adapted in part from [4-6]. Table 1: Table 1: Sudden cardiac arrest and death in trained athletes 2014–2018.

TABLE 1: Sudden cardiac arrest and death in trained athletes 2014–2018	**SURVIVAL**	**DEATH**
Males	**136**	**141**

Journal Pre-proof

Mean age (range)	16.5 (12–27)	16.9 (11–29)
Middle school	22	29)
High school	108	96
College athletes	21	23
Semiprofessional/professional	4	7
Basketball	43	95
Football	34	84
Soccer	22	39
Track/cross country	17	31
Baseball	14	21
Swimming	4	11
Lacrosse	6	9
Ice hockey	4	8
Wrestling	3	7
Softball	2	6
Volleyball	3	5
Tennis	1	4
Boxing	0	1
Crew	1	1

Performance enhancing drug use by athletes, such as anabolic-androgenic steroids, stimulants, oxygen-carrying modulators, and alcohol consumption can also contribute to the sudden death rate. Moreover, an incorrect diagnosis of cardiac pathology by a physician can lead to an unnecessary restriction of an athlete training and competition with resultant significant emotional, psychological, financial, and long-term health consequences in the athlete [6].

Currently, athlete screening for participation in sports is practiced in the United States by obtaining a personal and family history and performing a physical examination often without obtaining an ECG. In this regard, physicians who evaluate trained athletes must thoroughly inquire about cardiopulmonary symptoms, a family history of cardiovascular disease and sudden death in individuals <40 years, the use of drugs that increase athletic performance, and perform a complete physical examination with special emphasis on the cardiovascular examination. Positive responses by the athlete to questions about exertional chest pain, palpitations, shortness of breath out of proportion to the level of exertion, near syncope or syncope, a family history of cardiovascular

Journal Pre-proof

disease (CVD) or sudden death at age ≤40, or the identification of a heart murmur on physical examination that is indicative of heart disease require additional investigations to exclude the presence of significant cardiovascular disease (CVD) [7, 8]. The investigations should include an ECG, a transthoracic echocardiogram, and in athletes in whom the diagnosis is uncertain, a maximal exercise stress test or a continuous ECG recording, and cardiac magnetic resonance imaging (CMR) or a cardiac computed tomography angiography (CTA) scan of the heart when definition of the coronary anatomy or characterization of the aorta and the aortic great vessel morphology is indicated. The purpose of such screenings is the identification of athletes with potentially lethal cardiovascular diseases so that 1) the personal risk is decreased and the athletic field is a safer environment, and 2) athletes at high risk for cardiac arrest and sudden death are recognized and appropriately treated [7, 8].

This article discusses the characteristics of normal athlete cardiac remodeling, the cardiac changes with hypertrophic, dilated or arrhythmogenic right ventricular cardiomyopathy in the athlete, the use of the ECG and the echocardiogram in the differentiation of the normal athlete heart from the hearts of athletes with cardiomyopathies, and the treatment of athletes with cardiomyopathies. Hypertrophic cardiomyopathy and variants is frequent cause of sudden death in competitive athletes in the United States [3]. Arrhythmogenic right ventricular (RV) cardiomyopathy is the cardiac disease most commonly associated with cardiac sudden death in athletes in Italy [3].

THE NORMAL COMPTETIVE ATHLETE HEART

Early investigations of athletes that participated in regular intense exercise and competition reported that that cardiac volumes could be as much as 60% to 80% greater in athletes who participate in dynamic exercise, such as running a marathon, in comparison with non-athletes [9, 10]. Intense, repetitive dynamic exercise in athletes was reported to increase the ventricular and atrial volumes, increase stroke volume, enhance diastolic function, preserve LV wall thickness, and increase LV mass (where LV mass (g) = 0.8(1.04[[LV end-diastolic dimension + the end-diastolic interventricular septal wall thickness, + end-diastolic posterior wall thickness]^3 - LV internal end-diastolic dimension}^{3} + 0.6} [11]. In athletes who participate in regular intense static exercise and competition, such as weight lifting, cardiac mass was reported to be as much as 35% greater in athletes than in non-athletes due to large increases in systolic blood pressure and systemic vascular resistance [9, 10]. These changes were associated with increases in LV wall thickness but no significant changes in ventricular or atrial volumes or systolic function.

Journal Pre-proof

Although the early descriptions of cardiac remodeling in endurance athletes is correct today, recent investigations indicate that substantial increases in LV wall thickness or cardiac mass in trained athletes who perform static exercise should raise clinical suspicions of athlete sustained systemic hypertension, the use of anabolic steroids, or the presence of cardiac pathology such as hypertrophic cardiomyopathy [1,12]. Furthermore, all forms of competitive sports today involve different amounts of dynamic and static exercise. Consequently, the cardiac remodeling in today's athlete reflects the relative contributions of dynamic and static hemodynamic stresses. For example, the competitive crew rower develops an increase in LV volume and also a thickening of the LV myocardial wall due to the rhythmic increases in systemic blood pressure that occur during participation in this sport. Participation in soccer, basketball, and hockey also encompass significant components of dynamic (endurance) and static (strength) exercise training. FIGURE 1. Illustrates the different cardiac remodeling changes that can occur with variable amounts of dynamic and static exercise. FIGURE 1 is

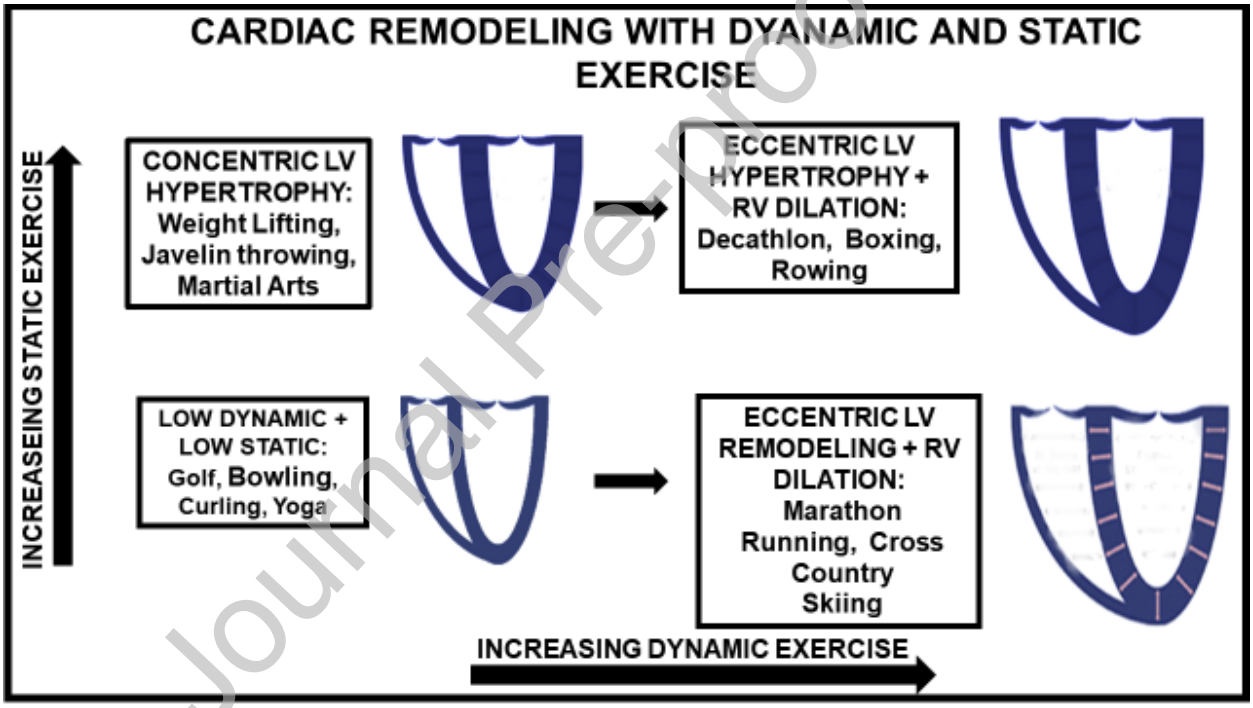

Adapted in part from [13].

Athletes who participate in high static and low-to-moderate dynamic sports, such as competitive wrestling, can develop mild LV hypertrophy with normal or even slightly reduced LV chamber size [13]. Athletes who regularly participate in low static, high dynamic exercise such as marathon running can experience LV remodeling with LV and RV dilation. Trained athletes who engage in high dynamic and high static sports such as crew rowing can develop physiological dilation of the right ventricle and both atrial chambers often accompanied by eccentric LV remodeling [13]. When LV wall thickening occurs in normal Caucasian trained athletes, the LV wall measurement is usually at the upper limits of normal at 12-13 mm and 15 mm in Black athletes but may exceed these measurements in elite athletes

Journal Pre-proof

[14]. In addition, the electrocardiogram is helpful in distinguishing the athlete with cardiac remodeling due to training from the athlete with cardiomyopathy.

THE ELECTROCARDIOGRAM IN THE TRAINED ATHLETE

The International Criteria for the electrocardiographic interpretation in athletes are the current "gold standard" for the ECG interpretation in athletes [15, 16]. The ECG changes that are considered normal in trained athletes with cardiac remodeling based on the International Criteria are listed in TABLE 2. TABLE 2 is adapted in part from the International Criteria [15, 16]. Open access to ECG modules based on the International Criteria are available at https://uwsportscardiology.org/e-academy.

NORMAL ELECTROCARDIOGRAPHIC CHANGES IN TRAINED ATHLETES	
INCREASED QRS VOLTAGE:	S wave V1 + R wave V5 or V6 >3.5mV (35mm) or R wave in V1 + S wave V5 or V6 ≥1.1mV (11mm)
INCOMPLETE RIGHT BUNDLE BRANCH BLOCK (IRBBB):	rSR' pattern in V1 and qRS in V6 with the QRS duration <120 msec.
EARLY REPOLARIZATION:	J point elevation, ST elevation, or QRS terminal slurring in the inferior and/or lateral leads.
BLACK ATHLETES: EARLY REPORIZATION VARIANT	J point elevation, Domed ST segment elevation with T wave inversion in V1-V4.
JUVENILE (<16 YEARS) T WAVE PATTERN:	T wave inversion in V1-V3.
SINUS BRADYCARDIA:	Heart rate >30 beats/minute but <60 beats/minute.
ECTOPIC ATRIAL RHYTHM:	P wave morphology different from sinus P wave morphology.
JUNCTIONAL ESCAPE RHYTHM:	QRS rate faster (<100) than resting sinus or ectopic atrial rate.

Journal Pre-proof

FIRST DEGREE ATRIOVENTRICULAR BLOCK:	**PR interval 200 to 400 msec.**
WENKEBACH (TYPE 1 SECOND DEGREE AV BLOCK	**PR interval progressively increases until there is a non-conducted P wave.**

Journal Pre-proof

As many as 64% of trained athletes fulfill the international Criteria for LV hypertrophy and the presence of isolated QRS voltage criteria for LV hypertrophy (LVH) does not correlate with cardiac pathology in athletes [15, 16]. Female athletes in comparison with male athletes have lower QRS voltages, shorter QRS duration, and a lower prevalence of LV hypertrophy by voltage criteria, regardless of the sport participation. In addition, T wave inversion in ECG V1 and V2 is more prevalent in women but T wave inversion in ECG lead V3 requires that ACM be ruled out.

ECG criteria for incomplete right bundle branch block or right ventricular hypertrophy (RVH) can occur in normal trained athletes and these ECG findings are a result of increased right ventricular (RV) size and increased cardiac electrical conduction time secondary to intense dynamic exercise. Isolated QRS voltage for RV hypertrophy does not inevitably correlate in athletes with cardiac pathology such as ACM or pulmonary arterial hypertension [17].

In Black trained male athletes, J point elevation and "domed" ST segment elevation followed by T wave inversion in the anterior precordial leads (V1-V3 or V4) is a normal ECG finding but occurs in only 2.7% of white athletes [18]. Furthermore, regression of anterior T-wave inversions in Black athletes can occur as early as 6 weeks after total cessation of exercise [18]. In contrast, T-wave inversions confined to the anterior precordial ECG leads (V1-V3) are uncommon in athletes with hypertrophic cardiomyopathy (HCM). However, T-wave inversions in the lateral precordial leads (V5-V6) occur in as many as 77% of the athletes with HCM [19]. In addition, over 90% of athletes with HCM have deep T wave inversions in the inferolateral leads, ST-segment depressions, pathologic Q waves, and intraventricular conduction delays ≥140 msec. [20, 21]. See FIGURE 2. FIGURE 2A is a normal ECG

from a normal Black competitive athlete. FIGURE 2B is an ECG from an athlete with HCM that demonstrates QRS voltage criteria for LVH in association with deep T wave inversion and ST segment depression predominantly in the ECG lateral leads (I, aVL, V4–V6), left and right atrial enlargement, and

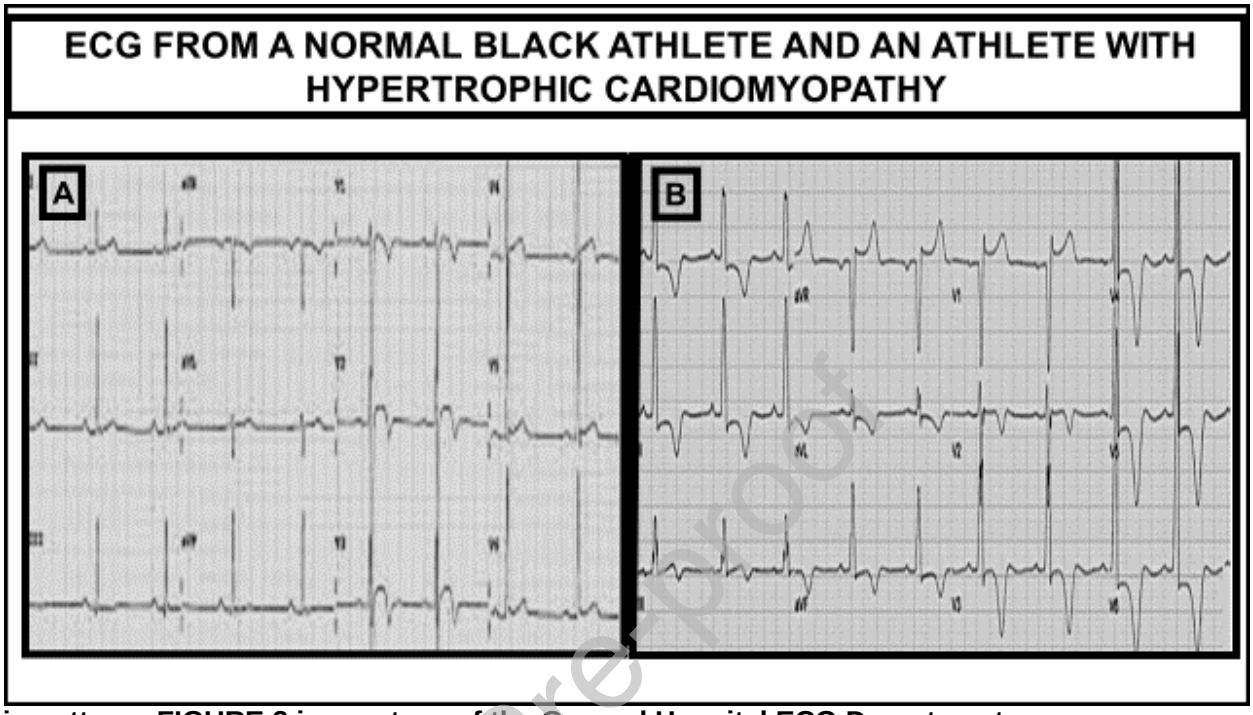

LV strain pattern. FIGURE 2 is courtesy of the General Hospital ECG Department.

In addition, early repolarization on the ECG consisting of J-point elevation with concave ST segment elevation and peaked T waves in the ECG precordial leads can occur in as many as 45% of Caucasian athletes and 63 to 91% of Black athletes of African-Caribbean descent [18-21]. Isolated inferior ECG T-wave inversions in trained male athletes can involve ECG leads III and AVF and do not represent a malignant phenotype [18]. However, Inferolateral T-wave inversion, ST-segment depression and/ or Q waves should always raise suspicion of underlying cardiac pathology such as HCM in a young athlete [21].

BORDERLINE ECG CHANGES IN TRAINED ATHLETES

TABLE 3 lists the ECG changes that are considered borderline between normal and abnormal athletes. The presence of any two of the ECG findings listed in TABLE 3 is abnormal and requires further investigation of the athlete by the physician. TABLE 3 is adapted in part from the International Criteria from [15, 16].

TABLE 3. Borderline ECG Changes in Athletes.

Journal Pre-proof

BORERLINE ELECTROCARDIOGRAPHIC CHANGES IN TRAINED ATHLETES: TWO OR MORE BORDERLINE ECG CHANGES REQUIRES ADDITIONAL INVESTIGATION	
ECG LEFT AXIS DEVIATION:	Frontal Plane ECG Axis -30 to -90 degrees.
LEFT ATRIAL ENLARGEMENT:	P wave >120 msec. with negative portion of the P wave ≥0.1 mV (≥1mm) in depth and >40 msec. in duration.
ECG RIGHT AXIS DEVIATION:	Frontal Plane ECG Axis >120 msec.
RIGHT ATRIAL ENLARGEMENT:	P wave ≥0.25 mV (≥2.5 mm) in ECG leads II, III, or AVF.
RIGHT BUNDLE BRANCH BLOCK:	rSR' in V1 and S wave wider than R wave in V6 with QRS ≥120 msec.

Isolated ECG changes of left or right axis deviation, or voltage criteria for atrial enlargement, or the presence of complete right bundle branch block (RBBB), are categorized as 'borderline' findings in athletes by the International Criteria for electrocardiographic interpretation [15, 16].

Isolated frontal plane axis deviation and voltage criteria for atrial enlargement account for a large number of ECG patterns that are classified as "abnormal" in athletes but do not correlate with cardiac pathology. Echocardiographic evaluation of athletes with isolated left axis deviation or with voltage criteria for atrial enlargement have not identified major cardiac structural or functional abnormalities, and the prevalence of minor congenital abnormalities is similar in these individuals in comparison with individuals with normal ECGs [22].

Left axis deviation or left atrial enlargement can reflect a relative increase in LV and left atrial dimensions in some athletes while right axis deviation and right atrial enlargement that occur in isolation or in association with other electrical markers of the normal athlete's heart' listed in TABLE 2 are probably normal cardiac variants [15, 16, 23]. Athletes in response to intense physical exercise can exhibit complete RBBB with increased RV dimensions and stretching of the right bundle in the heart with resultant increase in the RV conduction time and a decreased RV ejection fraction but preserved RV fractional area change [24]. In contrast, the presence of left bundle branch block in an athlete is definitely abnormal and requires further cardiovascular investigation.

Journal Pre-proof

In summary, the presence of any one of the borderline ECG changes does not warrant further cardiac assessment in totally asymptomatic athletes without a family history of premature cardiovascular disease or sudden cardiac arrest. In contrast, the presence of two or more of the borderline ECG changes warrants further investigation with cardiac imaging studies such as echocardiography, especially in athletes with a family history of premature cardiovascular disease or sudden death [15, 16].

ABNORMAL ECG CHANGES IN TRAINED ATHLETES

TABLE 4 lists the ECG changes that are abnormal in trained athletes. TABLE 4 is adapted in part from [15, 16].

ABNORMAL ELECTROCARDIOGRAPHIC CHANGES IN TRAINED ATHLETES	
T WAVE INVERSION	>0.1 mV (>1mm) in two contiguous ECG leads, except leads III, AVR, and V1 observed in anterior, lateral, infero-lateral or inferior leads
ANTERIOR T WAVE INVERSION V2-V4:	Exclude Blacks, Athletes <16 years, and biphasic T waves in V3
LATERAL T WAVE INVERSION:	ECG Leads 1, AVL, V5- V6
INFERO-LATERAL T WAVE INVERSION:	ECG Leads II, AVF, AVL, V5 and/or V6
INFERIOR T WAVE INVERSION:	ECG Leads II and AVF
ECG ST SEGMENT DEPRESSION:	Depth ≥0.05 mV (≥0.5 mm)in two or more contiguous ECG leads
PATHOLOGICAL Q WAVES:	Q/R ratio ≥0.25 or Q wave duration >40 msec. in two contiguous leads except III, AVR.
LEFT BUNDLE BRANCH BLOCK:	ECG QRS ≥ 120 msec. with QS or rS in V1 with notched or slurred R wave in 1 and V6

Journal Pre-proof

NON-SPECIFIC INTRAVENTRICULAR CONDUCTION DEFECT:	**ECG QRS ≥ 140 msec.**
EPSILON WAVE:	**V1-V3: Small positive deflection or notch between end of QRS and onset of T wave**
VENTRICULAR PRE-EXCITATION (WOLFF - PARKINSON-WHITE SYNDROME):	**PR < 120 msec., slurred upstroke of QRS (delta wave) and QRS duration ≥120 msec.**
PROLONGED ECG QT INTERVAL WHEN CORRECTED FOR THE HEART RATE:	**Males ≥470 msec., Females ≥480 msec., Markedly prolonged QT ≥ 500 msec.**
BRUGADA TYPE 1 PATTERN:	**>0.2mV (>2 mm) coved ST segment elevation with symmetric T wave inversion in ≥1 lead in V1-V3**
SINUS BRADYCARDIA:	**<30 beats/min. or sinus pauses ≥3 seconds**
FIRST DEGREE ATRIOVENTRICULAR BLOCK	**PR interval >400 msec.**
SECOND DEGREE ATRIOVENTRICULAR BLOCK (MOBITZ TYPE II):	**Intermittently non-conducted P waves with a fixed PR interval.**
THIRD DEGREE ATRIOVENTRICULAR BLOCK:	**Complete heart block with no P waves conducted to the ventricles.**
ATRIAL TACHYARRHYTHMIAS:	**Supraventricular tachycardia, atrial fibrillation, atrial flutter**
PREMATURE VENTRICULAR CONTRACTIONS:	**≥2 Premature ventricular contractions/10 sec, ventricular couplets, triplets, and non-sustained ventricular tachycardia**
VENTRICULAR DYSRHYTHMIAS:	**Couplets, Triplets, Non-sustained**

Journal Pre-proof

	ventricular tachycardia

T wave inversions are the most consistent electrical abnormalities in athletes with cardiomyopathies. ECG T wave inversion ≥1 mm in depth in two or more contiguous ECG in the anterior (V2-V4) , lateral (I and AVL, V5 and/or V6), inferolateral (I and aVF, V5-V6, I and AVL) or inferior (II and aVF) areas are not normal and require further investigation of the athlete for structural heart disease [15, 16]. ECG exceptions include T wave inversions in leads aVR, III and V1 or T wave inversions limited to the anterior precordial ECG leads V1-V4 in Black athletes and precordial leads V1-V3 in athletes less than 16 years of age. In athletes >35 years of age or athletes with ECG T wave inversions and cardiac risk factors, coronary artery disease must be ruled out with stress testing or a coronary computerized axial tomography (CAT) angiogram [15, 16]. The most common cardiac causes of morbidity and mortality in older athletes are atherosclerotic coronary disease, hypertensive heart disease, atrial fibrillation, and degenerative aortic and mitral valve disease [14].

FIGURE 3A demonstrates the ECG an athlete with ACM. The presence of T wave inversions in the ECG right precordial leads (V1-V3) or beyond occurs frequently among athletes with ACM and must be distinguished from the athlete with RBBB [24, 25]. Importantly, the presence of Epsilon waves, which reflect delayed ventricular depolarization potentials in the right ventricular outflow tract, indicate athletes prone to recurrent ventricular tachycardia. See arrows in FIGURE 3A. Epsilon waves may also be present in the ECGs of athletes with pulmonary embolism, infarction of the right ventricle, and sarcoidosis [25, 26]. Other ECG changes that can occur with ACM include low voltage in the limbs leads and premature ventricular contractions (PVCs) that originate from the RV with a superior frontal plane axis. Physicians must recognize this abnormal ECG pattern because intense and prolonged exercise in athletes with ACM can significantly worsen the disease and increase the risk of dysrhythmias.

Journal Pre-proof

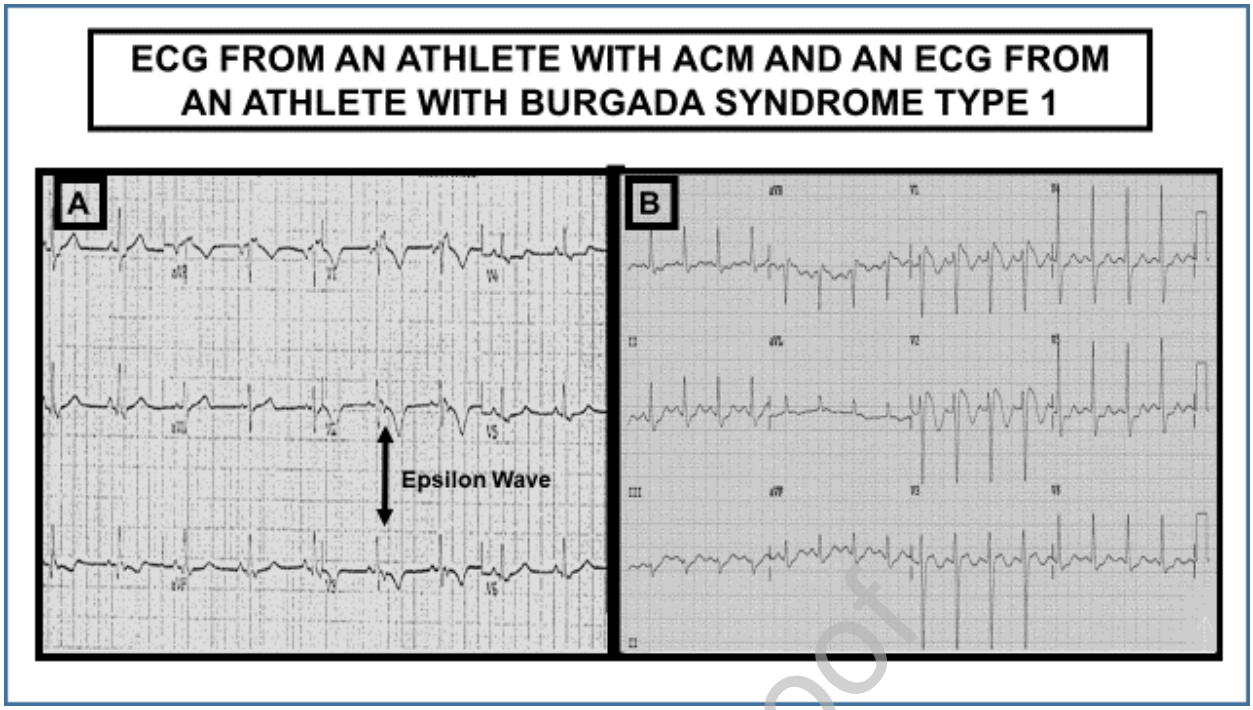

FIGURE 3 B is an ECG from an athlete with Brugada Syndrome Type 1, which is associated with sudden cardiac arrest and death. Note the 0.2 mV J point elevation, the coved ST segment elevations and the T wave inversions in ECG precordial leads V1-V3. This ECG pattern should not be confused with the ECG from a normal Black athlete which is illustrated in FIGURE 2A. FIGURE 3 is courtesy of the General Hospital ECG Department.

Deep T wave inversion, especially in the inferolateral leads, ST-segment depressions, pathologic Q waves, profound intraventricular conduction delays (140 msec. and complete LBBB commonly occur in hypertrophic cardiomyopathy but are considered normal physiologic findings in athletes [15, 16]. Similarly, T wave inversions frequently occur in athletes with dilated cardiomyopathy (DCM) but are often associated with low QRS voltages, left atrial enlargement, left axis deviation, pathological Q waves, LBBB or RBBB, premature ventricular contractions and atrial fibrillation, which are uncommon ECG findings in healthy athletes.

Although ECG anterior biphasic T waves are normal in athletes <16 years and in adults when present in a single lead such as V3, biphasic T-wave inversions can occur in athletes and are abnormal if the negative deflection of the T-wave exceeds ≥0.1 mV (1 mm) in ≥2 contiguous leads [14-16]. Biphasic T waves can reflect abnormal RV repolarization, electrolyte imbalance such as hypercalcemia, or the presence of coronary artery disease.

Trained athletes with LVH and thin adolescent athletes can have increased anterior precordial voltages and deep lateral or inferior Q waves. However, pathological Q waves, with a Q/R ratio ≥0.25 or a Q wave ≥40 msec. in duration in two or more leads other than lead III and aVR are abnormal and can occur in as many as 42% of patients with HCM [27]. The use of the Q/R ratio ≥0.25 decreases the false-

Journal Pre-proof

positive rate in trained athletes without compromising the sensitivity for the detection of cardiomyopathy [26, 27].

Pathological Q waves in athletes can also be due to misplacement of the ECG precordial leads, the Wolff-Parkinson-White (WPW) Syndrome or transmural myocardial infarction. The WPW pattern occurs in approximately 1/1000 athletes [8, 23]. In athletes with possible WPW syndrome, Epstein's anomaly, hypertrophic cardiomyopathy, and complex congenital heart disease should be ruled out [23].

Pathological Q waves in two or more contiguous ECG leads necessitates further investigation with echocardiography, stress testing, or cardiac MRI to exclude cardiomyopathy. In athletes >30 years of age or athletes with multiple cardiac risk factors, coronary artery disease must be ruled out.

Atrial or ventricular extrasystoles or tachycardia in athletes that emerge or intensify during exercise are abnormal until proven otherwise and require investigation. In older athletes, atrial tachydysrhythmias, including atrial fibrillation and atrial flutter, are common and correlate with the duration and intensity of sport participation. These athletes should undergo exercise stress testing or ambulatory heart rhythm monitoring to facilitate the diagnosis and treatment. In selected athletes with recurrent atrial dysrhythmias, invasive electrophysiology study should be performed to facilitate ablation treatment. In addition, an echocardiogram should be performed to evaluate the athlete for congenital heart disease or cardiomyopathies.

All medical personnel must recognize that an ECG correctly interpreted as normal or normal variant ECG does not rule out all cardiovascular conditions such as anomalous origin of the coronary arteries or premature atherosclerotic heart disease that can predispose an athlete to sudden cardiac arrest and death. Ten to 16% of sudden cardiac death cases have no associated electrical anomalies but can have structural abnormalities identified on echocardiography, MRI or CAT imaging procedures [28]. Consequently, all athletes with cardiovascular symptoms, a family history of sudden death or an abnormal physical examination or an abnormal ECG require a comprehensive investigation, including the use of imaging procedures such as echocardiography.

THE NORMAL ECHOCARDIOGRAM OF ATHLETES HEART

The echocardiogram has a significant diagnostic role in the evaluation of the athlete with cardiovascular symptoms, an abnormal physical examination or an abnormal ECG. The echocardiographic views of the athlete should include the parasternal long-axis, parasternal short-axis, the apical 4-chamber and 2-chamber views, the suprasternal, parasternal right and subcostal views. In addition, the echocardiogram should be interpreted by a physician who is familiar with the normal echocardiographic measurements in trained athletes.

Sport specific adaptions in the athlete heart visualized on the echocardiogram are dependent on the type of exercise, the intensity and the duration of exercise and whether the lower extremities, the upper extremities or both are primarily utilized by the athlete in exercise. TABLE 5 lists normal

Journal Pre-proof

echocardiographic reference mean measurements and 95% confidence intervals for athletes who consistently participate in the endurance sports (long-distance runners, swimmers, and cross-country skiers), power sports (bodybuilders and weightlifters), combined sports (rowers, cyclists, and speed skaters) or mixed sports (heterogeneous sports not characterized by the previous groups). TABLE 5 is adapted in part from [29-31]. TABLE 5 Normal echocardiographic reference mean value measurements and 95% confidence intervals for trained athletes.

ECHOCARDIOGRAPHIC PARAMATER	ENDURANCE SPORTS	POWER SPORTS	COMBINED SPORTS(Cyclists)	MIXED SPORTS (Basketball)
LV Diameter, mm	55 (50.2-59.8)	54 (46.9-61.2)	53.2 (47-59.4)	54.8 (47.8-61.8)
LV Septum, mm	10.7 (7.7-13.7)	11.5(10.3- 2.7)	11.7 (9.9-13.5)	11.4 (9.8-13)
Posterior LV Wall, mm	10.7 (8.1-13.3)	11.0(10.2-1.8)	11.2 (10.6-11.8)	11.2 ((9.0-13.4)
LV Mass, grams	241 (153-329)	243 (177-309)	244 (186-302)	252 (168-336)
Mitral Valve E wave, m/s	0.771 (0.615-0.927)	0.833(0.651-1.012)	0.868(0.572-1.164)	0.838 (0.496-1.18)
Mitral Valve A wave, m/s	0.461(0.345-0.577)	0.5539(0.353-.753)	0.505(0.335-0.675)	0.436(0.248-0.624)
RV basal diameter	40 (38-42)	38 (31-45)	44 (39-49)	43 (41-44)
PLAX RVOT mm	29 (26-33)	29 (26-33)	29 (26-33)	29 (26-33)
RV Wall, mm	4.2 (3.9-4.4)	4.0 (3.0-5.0)	7.0 (5.0-8.0)	ND
Fractional Area Change, %	35 (32-38)	41 (32-49)	36 (32-40)	43 (36-51)
TAPSE	25 (22-28)	25 (22-28)	25 (22-28)	25 (22-28)
Strain %	-24.7 (22.9-26.4)	-24.7 (22.9-26.4)	-24.7 (22.9-26.4)	-24.7 (22.9-26.4)

Journal Pre-proof

RV E/A ratio	**1.71 (1.57-1.84)**	**1.71 (1.57-1.84)**	**1.71 (1.57-1.84)**	**1.71 (1.57-1.84)**
RV e' m/s	**0.18 (0.14-0.22)**	**0.18 (0.16—0.20)**	**0.12 (0.10-0.14)**	**0.16 (0.16-0.20)**

LV mass (g) = 0.8(1.04(LVIDD + IVST + PWT)3 LVIDD3) + 0.6, where LVIDD is LV internal end-diastolic dimension, IVST is the end-diastolic interventricular septal wall thickness, and PWT is end-diastolic LV posterior wall thickness; RVOT is the parasternal long axis echocardiographic measurement of the right ventricular outflow tract; Fractional area change is the percent difference between RV end-diastolic and end-systolic areas measured through the apical view of the RV; TAPSE is the Tricuspid Annular Plane Systolic Excursion; RV e' is the peak early diastolic tricuspid annular tissue velocity; ND is data not available.

Most Caucasian trained athletes have a maximal LV wall thickness of approximately 12 mm but in approximately 2% of Caucasian athletes a borderline measurement between 13-16 mm can occur [29]. In female athletes the upper limit of normal for LV wall thickness is <11 mm with a borderline measurement between 11-13 mm [29]. Caucasian athletes with echocardiographic measurements that exceed the upper 95% confidence limit warrant further evaluation to exclude hypertrophic cardiomyopathy and/or regular follow-up if the athlete is asymptomatic and displays no symptoms or other abnormalities. Black male athletes can demonstrate normal LV wall thicknesses up to 14 to 15 mm and black female athletes can demonstrate LV walls thicknesses of 11 to 13 mm [32, 33]. LV wall measurements ≥15 mm in Black athletes should raise questions of cardiac pathology and warrant further investigation [33].

Asymmetric LV hypertrophy in Black or Caucasian athletes is abnormal and warrants further cardiac investigation [34]. Exercise-induced ventricular chamber thickening in a normal athlete's heart is at least partially reversible after detraining whereas ventricular hypertrophy in athletes with HCM should not change significantly with detraining [1, 35]. Additional differentiation of physiologic from pathologic changes in the athlete ventricle can be obtained by determination of the relative wall thickness (RWT). The RWT is the ratio of the sum of the interventricular septum and posterior wall thickness in end-diastole to the left ventricular end-diastolic diameter. Values between 0.30 and approximately 0.42 in athletes are compatible with physiologic LV remodeling whereas athletes with values >0.45 are not normal and require investigations for possible pathologic LV changes [14, 36].

The athlete who consistently participates in intense dynamic exercise develops a heart with eccentric LV remodeling, an increased LV diameter in diastole (LVIDd) and end-diastolic volume (LVEDV) and normal or slightly increased LV wall thickness. In the athlete who participates in static exercise, the LV wall measurement can be normal or increased and the LV end-diastolic volume is

Journal Pre-proof

within the normal range [33]. Although elite Olympic athletes may have LVIDd up to 70 mm in males and up to 66 mm in elite female athletes, LVIDd > 59 mm in most male athletes and LVIDd >53 mm in female athletes warrants further investigation or at least careful follow-up if the athlete is totally asymptomatic [36, 37]. Indexing the LV diameter to body surface area (BSA) facilitates the athlete evaluation by physician(s) and comparisons with other trained athletes. The upper limit for the LV diameter/BSA in male athletes is <35 mm/m² and in female athletes is <40 mm/m² [36].

In endurance athletes with LV cavity dilation, cardiac output can increase five to six-fold during maximal exercise. The increase in cardiac output is due to sympathetic nervous system activation and withdraw of parasympathetic nervous system stimulation with resultant increases in cardiac preload (ventricular end-diastolic volume), heart rate and stroke volume [14].

Training-induced right ventricular (RV) enlargement is frequent in endurance athletes. Moreover, RV enlargement >50 mm in end-diastolic diameter, which is suggestive of a diagnosis of ACM, can occur in as many as 30% of elite athletes participating in endurance and mixed sports [36, 37]. Conversely, in athletes participating in power sports, RV end-diastolic diameter measurements are more commonly ≤31 mm [30]. Importantly, physiologic RV dilation in endurance athletes result in proportional increases in the RV outflow and inflow tracts such that despite the global RV enlargement the RV outflow/inflow ratio remains similar to the non-athlete population. In these athletes a normal RV outflow/inflow ratio of 0.8 ± 0.1 contrasts with a predominant increase in the outflow tract in athletes with ACM and a RV outflow/inflow ratio >1.0 [38]. In addition, a basal end-diastolic RV: LV diameter ratio of 0.8 ± 0.1 in the long axis on echocardiogram is helpful in differentiating physiologic from pathologic RV dilation in athletes with ACM where the RV: LV diameter size ratio is >1.2 in ACM [39].

LV remodeling in endurance athletes is associated with normal or increased LV myocardial relaxation. Trained endurance athletes can have enhanced early diastolic LV filling with an increased mitral valve E-wave velocity, a decreased mitral valve A wave velocity, and an E/A ratio >1-2, In addition, Doppler mitral annular tissue velocities (e') can be supernormal (i.e. >9 cm/sec), and can contribute to a low E/e' ratio [40].

LV global longitudinal strain (LV-GLS) measurements in normal athletes in endurance sports and mixed sports vary between approximately -15 and -22% and LV GLS and LV global circumferential strain (GCS) are decreased on average 10% and 11%, respectively, in comparison with non-athletes [41]. Interesting, RV GCS can decrease by approximately 15% in endurance and mixed sport athletes in comparison with non-athletes and can exceed the 2% decrement in RV GLS in athletes. This RV mechanical pattern in athletes is thought to facilitate increased exercise capacity [41]. Importantly, a resting LV-GLS and a RV GLS value <-15% in athletes warrants further investigation of the athlete, especially if other concomitant echocardiographic measurements are abnormal.

Left ventricular resting ejection fractions in athletes that participate in endurance, power, and mixed sports average 60 percent but can range from approximately 50 to 72% [41]. However, some elite

Journal Pre-proof

marathon runners and professional basketball players have resting LV ejection fractions of 45-49% [42]. In these athletes, increased ventricular preload, ventricular dilation, increases in ventricular ejection time, and decreased systemic vascular resistance can contribute to a normal stroke volume at rest and an increased stroke volume with exercise. The LV ejection fraction in normal athletes should increase by as much as 11% with near maximal exercise, in contrast to the athlete with a dilated cardiomyopathy in whom the LV ejection fraction does not significantly change or decreases with exercise [43-45].

Although RV ejection fraction in athletes (52± 8%) is similar to non-athletes (54±6%), reductions in RV global systolic function assessed by RV ejection fraction or by RV fractional area change can also occur in highly trained endurance athletes with RV dilation [37, 45-47]. For example, in elite endurance athletes, RV ejection fractions of 40-45% can occur [47]. Nevertheless, the RV regional wall motion is always preserved in normal athletes and the identification of regional RV wall motion abnormalities in an athlete is abnormal and warrants investigation of the athlete for ACM or DCM.

The hemodynamic effects of intensive exercise can result in the enlargement of left atrium and the increase in atrial size can overlap with the atrial measurements of athletes with cardiomyopathy and patients with congestive heart failure. In this regard, left atrial size increases with the intensity and duration of sport participation [48]. The largest increases in atrial size occur in athletes who participate in endurance and combined sports but atrial size also increases in athletes who participate in power sports. In a meta-analysis of 54 studies that included 7,189 elite athletes and 1,375 controls, the upper limit of left atrial diameter in elite male athletes was 36.5 mm and 35.1 mm for LA diameter in female athletes [49]. In this meta-analysis, mean LA volume indexed for BSA was 30.8 ml/m^2 (CI: 26.1 to 35.5) in male elite athletes and 24.5 ml/m^2 (95% CI: 21.6 to 27.5) in male controls [49]. There was no statistically significant difference between male and female athletes in atrial volumes indexed for BSA in this study although the number of female athletes with atrial echocardiographic measurements was small. Reported echocardiographic atrial measurements in the medical literature vary due to different athlete populations and different number of athletes investigated. Nevertheless, left atrial volume measurements in athletes exceeding 35.5 ml/m^2 can occur but are less likely to represent physiologic adaptations to training and warrant investigation for structural heart disease. In addition, a LA volume index of >35.5 ml/m^2 can be predictive of adverse cardiovascular outcomes [50].

Speckle tracking echocardiography of the atria in trained athletes demonstrates a pattern of deformation with a decrease in the stiffness index, a normal reservoir function and a reduced active contribution of the atrium to ventricular filling at rest. These findings suggest in normal trained athletes that atrial emptying is increased in early diastole due to increased ventricular size and compliance and that the atrial contraction contribution to ventricular filling is decreased [50]. Interesting, the adaptation of LA size to intense training appears to be long lasting with residual LA enlargement persisting for many years after the end of the athletic career [51].

Journal Pre-proof

FIGURE 4 lists an algorithm of echocardiographic measurements that are useful in the differentiation of trained athletes with adaptive changes from the athlete with maladaptive/pathological

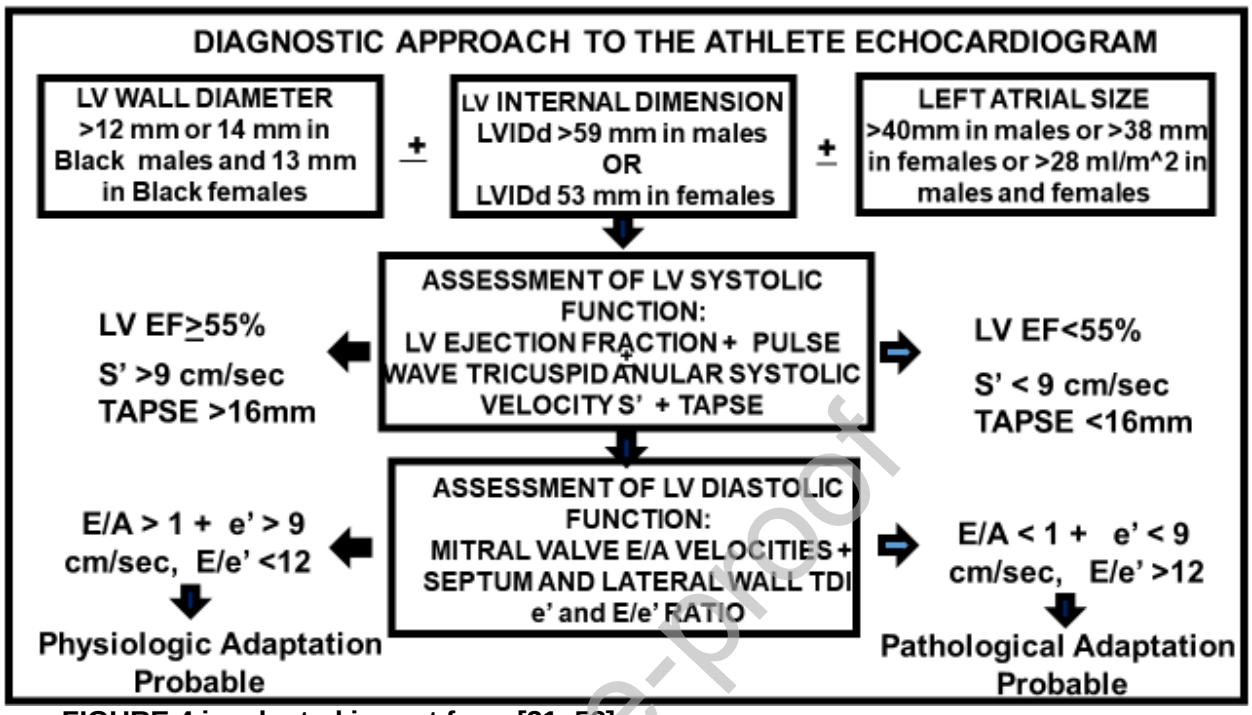

changes. FIGURE 4 is adapted in part from [31, 52].

Where LVIDd is the LV internal diameter in diastole; S' is the tricuspid lateral annulus systolic velocity; TAPSE is the tricuspid annular plane systolic excursion; E wave represents the early diastolic mitral valve blood flow velocity determined by Doppler during which blood flows from the left atrium into the left ventricle with passive filling; A wave represents the late diastolic mitral valve blood flow velocity during atrial contraction and rapid ventricular filling; e' is mitral annular tissue early relaxation velocity and is a measure of the rate of early diastolic lengthening and LV restoring forces.

TABLE 6 lists additional diagnostic techniques that are useful in evaluating athletes with abnormal echocardiographic measurements and is adapted in part in part from [31, 46, 52, 53].

TABLE 6: Diagnostic Tests Useful in Athlete Evaluation.

Journal Pre-proof

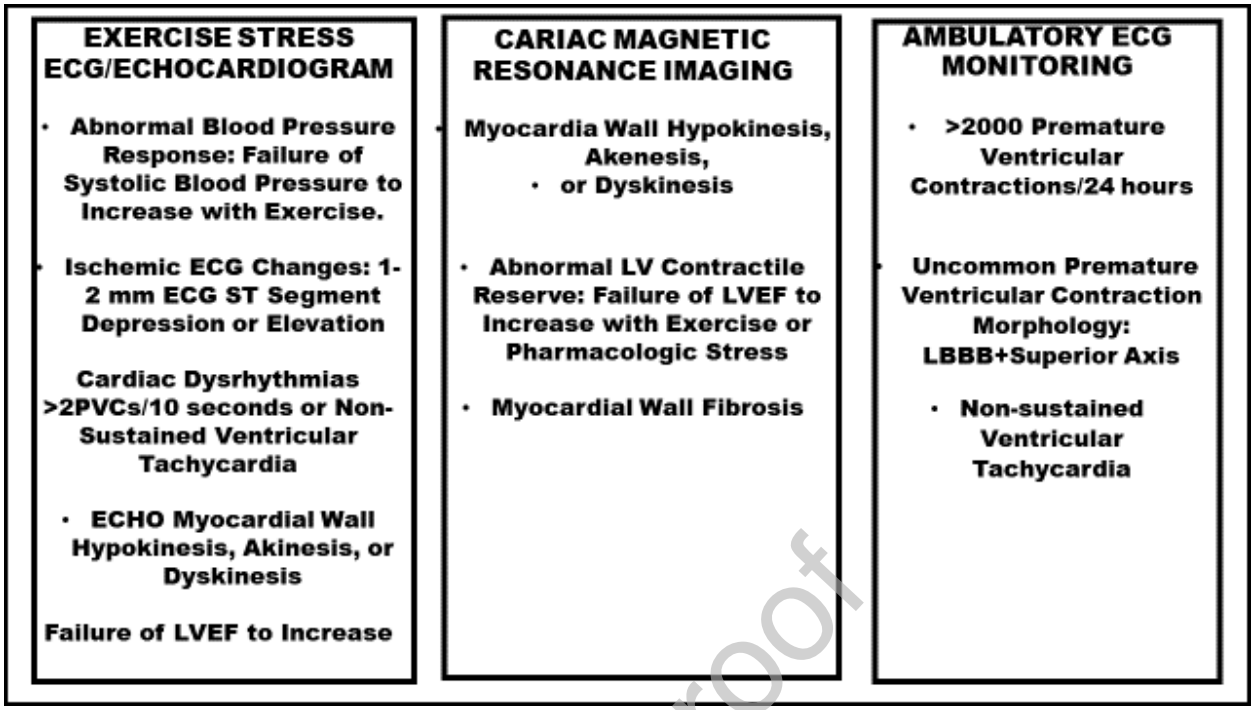

Journal Pre-proof

ECG/echocardiographic stress tests are useful in the detection of PVCs, non-sustained ventricular tachycardia, abnormal blood pressure responses to exercise, myocardial wall motion abnormalities, and the detection of ECG ST segment changes indicative of myocardial ischemia. CMR is useful in the detection of an impairment in LV or RV contractile reserve, a significant decrease in LV or RV global myocardial function and/or the presence of LV or RV myocardial wall motion abnormalities and the presence of myocardial wall late gadolinium contrast enhancement indicative of myocardial fibrosis. In addition, demonstration by heart monitoring recording of a PVC burden of ≥2000 PVCs per day, PVC morphologies of left bundle branch block with intermediate or superior axis in the frontal plane or complete RBBB,, and/or an increase in PVC frequency or runs of non-sustained ventricular tachycardia during exercise are signs of cardiac disease [46, 54]. Each of these test abnormalities warrant treatment of the athlete and reevaluation of sports participation by the physician and the athlete.

ATHLETES WITH HYPERTROPHIC CARDIOMYOPATHY

The prevalence of HCM in the United States is approximately 1:200 to 1:500 Americans [55]. This suggests that as many as 750,000 Americans can be affected by HCM. However, only a small fraction of the American population are actually diagnosed with HCM even though in the United States HCM is the single most common cause of deaths among athletes [55, 56]. Testing for HCM genes MYH7, MYBPC3, TNNI3, TNNT2, TPM1, MYL2, MYL3, and ACTC1 is helpful in athletes with possible HCM and, if positive, first degree relatives should be tested for HCM [57].

Transthoracic echocardiography is the most readily accessible and informative imaging technique for diagnosing HCM. In athletes with HCM, echocardiography provides quantitative measurements of the size and the location of the ventricular hypertrophy, provides assessment of any mitral valve-interventricular septum subaortic obstruction, characterizes the magnitude of mitral valve regurgitation, and estimates pulmonary artery systolic pressures. Echocardiographic measurements of LV wall thickness should be performed at end-diastole, preferably in short-axis views and all LV segments from base to apex should be examined with the wall thickness recorded at the mitral, mid-LV, and apical levels. In an adult, HCM is defined by a wall thickness ≥15 mm in one or more LV myocardial segments [57]. However, elite athletes participating in sports with high static and mixed sports can display profound LV remodeling that can be confused with HCM [38, 56]. Nevertheless, the presence of systolic anterior motion of the mitral valve against the interventricular system with a LV outflow tract (LVOT) pressure gradient is inconsistent with a diagnosis of athlete's heart and strongly suggests HCM in the athlete [55,57].

The LV outflow tract obstruction in HCM is caused by asymmetrical septal hypertrophy, an elongated mitral valve anterior leaflet which is often >30 mm in diameter (17 mm/m^2), apically displaced hypertrophied papillary muscles that tether the mitral valve apparatus toward the interventricular septum, and anterior motion of the mitral valve against the interventricular septum in mid-systole with >30% systolic contact [57]. See FIGURE 5.

FIGURE 5: HCM in an athlete. Apical 4 Chamber and Parasternal long Axis Echocardiographic Views

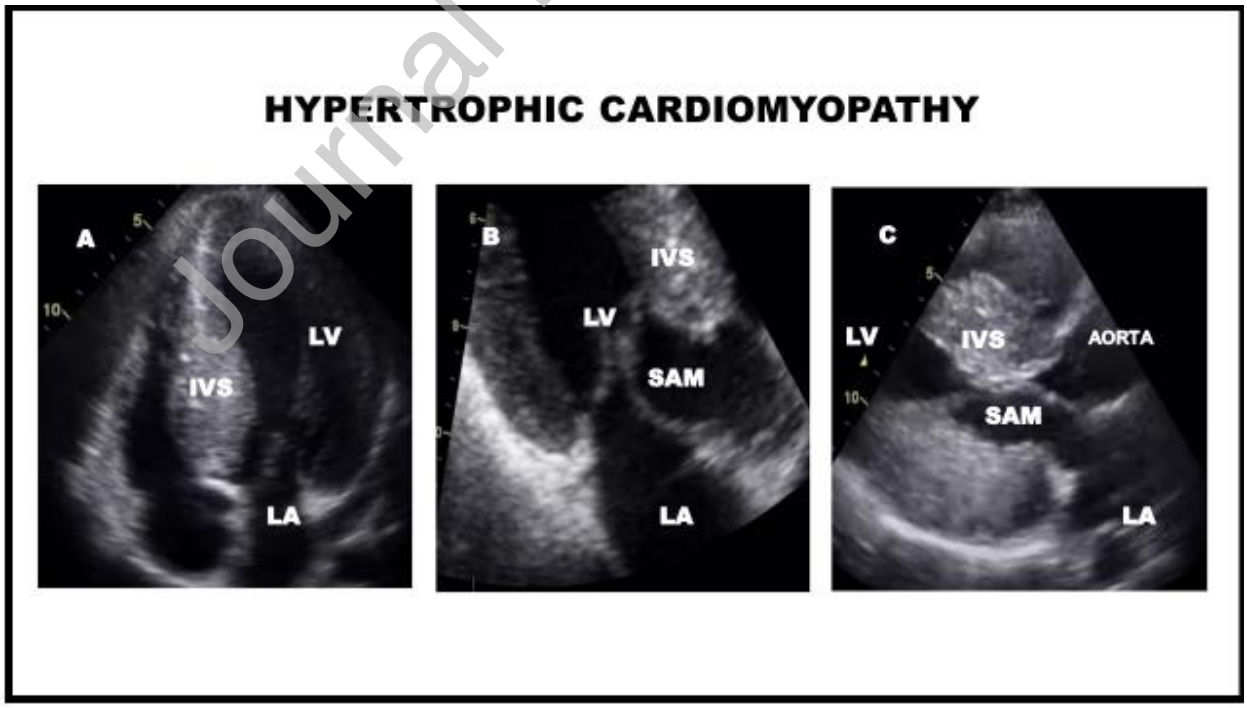

Journal Pre-proof

FIGURE 5: A: Apical 4 chamber echocardiographic view with septal hypertrophy; B: Apical 3 chamber view with mitral valve apparatus drawn toward the hypertrophied interventricular system; C: Parasternal long axis view with systolic motion of the anterior mitral valve leaflet against the interventricular septum with LV outflow tract obstruction. IVS: Interventricular Septum; SAM: Systolic Anterior Motion of the Mitral Valve; LV: Left Ventricle; LA: Left Atrium. FIGURE 5 is courtesy of the General Hospital Echocardiographic Department.

Athletes with HCM may have LV mitral valve-septal outflow tract (LVOT) pressure gradients <30 mm Hg at rest and with exercise termed nonobstructive HCM. Alternatively, athletes may have LVOT obstruction at rest with gradients ≥30 mm Hg, or pressure gradients ≥30 mm Hg with exercise or pharmacologic provocation which is termed obstructive HCM.

The LVOT pressure gradient in athletes with HCM can worsen with the Valsalva maneuver by decreasing LV filling and increasing the anterior mitral valve leaflet-interventricular septal contact. Left ventricular outflow tract obstruction is of major concern when the LVOT gradient is ≥50 mmHg at rest or with provocation [34, 55]. If bedside maneuvers such as the Valsalva maneuver fail to induce LV outflow tract obstruction ≥50 mm Hg in a symptomatic athlete, treadmill exercise stress echocardiography should be performed to determine if exercise provokes a LV outflow pressure gradient ≥50 mm Hg due to increased LV myocardial contractility. Additional features of HCM that can be uncovered with treadmill stress echocardiography include exercise-induced dysrhythmias, a decrease rather than an increase in systolic blood pressure in response to exercise, and delayed heart rate recovery after exercise [34].

Athletes with HCM can have apical LV hypertrophy rather than asymmetric septal hypertrophy and approximately 15% of athletes with HCM have concentric LV hypertrophy [58]. With either nonobstructive or obstructive HCM, interventricular and intraventricular conduction delays and myocardial dyssynchrony can occur in athletes even in the absence of electrical conduction abnormalities on the ECG. Dyssynchrony is measured by the standard deviation of the time from the onset of systole to maximum contraction for each of the myocardial segments and this measurement correlates with the degree and location of the LV hypertrophy and the presence of LV outflow obstruction. A dyssynchrony measurement of >45 msec. correlates over five years with an increased risk for ventricular dysrhythmias and sudden cardiac death with a test accuracy of 90.6% [59].

Athletes with HCM have LV cavity diameters <45 mm but LV cavity diameters of ≥55 mm occur primarily in athletes with HCM with LV systolic dysfunction and progressive heart failure [55, 60]. The left atrium (LA) is often enlarged because of mitral valvular regurgitation. A left atrial diameter >48mm is associated with adverse event such as atrial dysrhythmias [61].

Left atrial strain and strain rate measurements by echocardiography two-dimensional speckle tracking contributes to the differentiation of athletes with non-obstructive HCM from athletes with physiologic LV hypertrophy and left atrial dilation. Individuals with non-obstructive HCM in

Journal Pre-proof

comparison with athletes with LV hypertrophy and left atrial dilation have significantly smaller left atrial strain systolic waves (19 ± 8% vs. 43 ± 8%), left atrial strain rates during ventricular systole (0.7 ± 0.2 s-1 vs. 1.6 ± 0.2 s-1) and left atrial strain rate during atrial contraction (–0.8 ± 0.1 s-1 vs. –1.4 ± 0.3 s-1) [62]. These measurements are associated with impairment of left atrial deformation and decreased exercise capacity.

LV strain patterns can be used to assess the ventricular function of athletes with HCM and strain measurements appear to be more sensitive than LV ejection fraction in the diagnosis of cardiac dysfunction. In 64 individuals with HCM but preserved LVEF, global longitudinal and circumferential strain measurements were less than normal controls and correlated with increased NT-ProBNP and cardiac troponin T measurements [62, 63]. In a separate study of individuals with HCM with LV ejection fractions within a normal range, decreased global longitudinal strain was independently associated with a composite end-point encompassing new-onset sustained ventricular tachycardia/fibrillation, heart failure, cardiac transplantation, and all-cause death [64]. In this study, individuals with GLS -10% had 4 times the event rates compared with individuals with a GLS -16%. Athletes with HCM can also have LV diastolic dysfunction due to impaired ventricular relaxation and an E/A ratio ≥2, an E-wave deceleration time ≤150 msec. and an increased LV filling pressure with an E/e' >12–15 [63].

In athletes with ventricular hypertrophy in whom echocardiography is suboptimal, CMR can unmask focal hypertrophy involving the apex, anterior free wall or the posterior ventricular septum. Cardiac magnetic resonance imaging provides 1) Increased measurement precision of LV septal thickness by distinguishing and excluding the RV crista supraventricularis and the RV moderator band; 2) Quantitation of LV mass and function; 3) Identification and characterization of myocardial fibrosis with late gadolinium contrast enhancement (LGE); 4) and facilitation of surgical myectomy planning by detailing the anatomy of the LV outflow tract. Late gadolinium contrast enhancement during MRI examination can be seen in athletes with HCM most often in the area of maximal LV wall thickness and at the anteroseptal and inferoseptal segments of insertion of the right ventricle. However, LGE at the insertion sites of the RV into the septum can be seen in young, healthy endurance athletes without HCM and without myocardial ischemia [65, 66].

In order to distinguish HCM from physiologic hypertrophy, total cessation of exercise by the athlete for three to six or more months can be informative [35]. Athletes with physiologic LV hypertrophy can show reductions in LV wall thickness of 2 to 5 mm with total cessation of exercise. In contrast, reductions in LV wall thickness do not usually occur with the pathologic hypertrophy of HCM [55, 67].

The advantages and possible disadvantages or side-effects of HCM treatment should be thoroughly discussed with the athlete and treatment decisions should be acceptable to the athlete and to the physician. Athletes with nonobstructive HCM can be managed with pharmacologic therapy with β-adrenergic receptor antagonists, calcium channel antagonists, angiotensin-converting enzyme (ACE) inhibitors or angiotensin receptor blockers (ARB). Athletes with obstructive HCM with gradients ≥30

Journal Pre-proof

mmHg, are initially treated with β-adrenergic receptor antagonists, calcium channel antagonists, disopyramide, or cardiac beta-myosin inhibitors such as mevacamten [68]. If athletes are persistently symptomatic, experience unexplained syncope, or in athletes with HCM with substantial LV outflow pressure gradients ≥50 mm Hg, either at rest or with provocation, surgical ventricular septal myectomy or percutaneous catheter alcohol ventricular septal ablation can be performed [68]. Septal reduction therapy improve symptoms and relieves LV obstruction, but there is no data to date that shows that septal reduction therapy prevents sudden cardiac death in obstructive HCM. [68].

TABLE 7 lists echocardiographic parameters that predict adverse cardiac events in athletes with HCM.TABLE 7 is adapted in part from [55, 57, 61].

TABLE 7: Echocardiographic parameters that predict adverse cardiac events in HCM:

- **Maximal LV wall thickness >30mm: Threefold increased incidence of ventricular dysrhythmias.**
- **LVOT gradient at rest without provocation >30mmHg and a LV ejection fraction <50%: Increased incidence of heart failure and sudden death**
- **LVOT pressure gradient at rest or with exercise or pharmacologic provocation ≥50mmHg: Increased risk of heart failure, stroke, and sudden death.**
- **Left atrial diameter >48mm or left atrial volume >27ml/m^2: Increased incidence of atrial fibrillation.**
- **Intraventricular dyssynchrony >45 msec. due to LV hypertrophy or LV fibrosis: Increased incidence of ventricular tachycardia**
- **.Abnormal left atrial strain: Increased risk of atrial fibrillation.**
- **Abnormal LV global longitudinal strain: Increased risk of ventricular dysrhythmias, heart failure, and cardiac death**

The risk of adverse events significantly increases in athletes with two or more echocardiographic abnormalities. Risk stratification is paramount to assess the need for pharmacologic therapy, septal reduction therapy, and/or an implantable cardioverter-defibrillator [66, 69, 70]. In this regard, the European Society of Cardiology has proposed a sudden death risk calculator based on a study of 3675 individuals with HCM that provides individualized 5-year risk estimates using seven variables, including age, maximum LV wall thickness, left atrial size, LV outflow tract gradient at rest, family history of sudden cardiac death, nonsustained ventricular tachycardia or syncope not consistent with neurocardiogenic syncope [71, 72]. A similar risk calculator has been proposed by the AHA/ACC based on 506 individuals with HCM, and includes risk factors such as ≥ 15% LV late gadolinium contrast enhancement of LV mass and the presence of LV apical aneurysms on MRI examination, maximal LV wall thickness >30 mm, the presence of unexplained syncope, non-sustained ventricular tachycardia, a family history of sudden cardiac death, and an abnormal blood pressure response to

Journal Pre-proof

exercise or stress and is available at https://professional.heart.org/en/guidelines-and-statements/hcm-risk-calculator [57]. In athletes with HCM who have survived a cardiac arrest due to ventricular tachycardia or fibrillation, or who have experienced syncope or hemodynamic compromise from ventricular tachycardia, an automatic implantable cardioverter-defibrillator (ICD) is recommended. In athletes with HCM and sudden death risk scores >6%, an ICD should be strongly considered [71]. An ICD should not be placed solely to allow an athlete to return to sports competition [57, 71]. Physical examinations, electrocardiograms, and echocardiograms should be performed at least on an annual basis in athletes with HCM and an ICD to evaluate for new or increasing symptoms [61, 68]. Ambulatory ECGs or exercise stress tests and echocardiograms or cardiac MRI also should be performed at regular intervals in athletes who do not have ICDs to evaluate cardiac function, cardiac morphological changes, and possible provocable cardiac dysrhythmias.

ATHLETES WITH DILATED CARDIOMYOPATHY

Dilated cardiomyopathy (DCM) is characterized by a reduction in the LV ejection fraction to <35% or a LV fractional shortening <25%, a LV diameter >58 mm in males and >52 mm in females, and an increase in LV end-diastolic volume of >150mL (75 mL/m^2 in males and ≥62 mL/m^2 in females) in the absence of coronary artery disease (CAD), hypertension, or valvular heart disease [73, 74]. In this regard, healthy endurance or mixed sports athletes can develop physiological LV and RV dilatation with a borderline or mildly reduced ventricular (LV) ejection fractions that can simulate DCM [1, 74]. However, mitral valve regurgitation is usually absent in these athletes but present in individuals with DCM.

In athletes with DCM, LV dilation precedes LV systolic dysfunction and may be accompanied by RV dilation. Right ventricular dilation is defined as RV basal diameter at end-diastole of >41mm (RVD1), a RV mid-diameter at end-diastole >35mm (RVD2) and a RV longitudinal diameter at end-diastole >83mm (RVD3) [75]. With gradual dilatation, the LV becomes more spherical in DCM and the sphericity index value, which is derived by calculating ratio between the length of the mitral annulus to apex in the apical echocardiographic view and the width of the LV mid-cavity in the apical four chamber view, approaches 1 with a normal value >1.5. The sphericity index is a predictor of decreased exercise capacity in athletes with LV dysfunction and is an adverse prognostic marker [75]. See FIGURE 6.

FIGURE 6. Dilated Cardiomyopathies in senior athletes. A: Parasternal long axis echocardiographic view. B: Apical 4 chamber echocardiographic view. FIGURE 6 is courtesy of the General Hospital Echocardiographic Department.

Journal Pre-proof

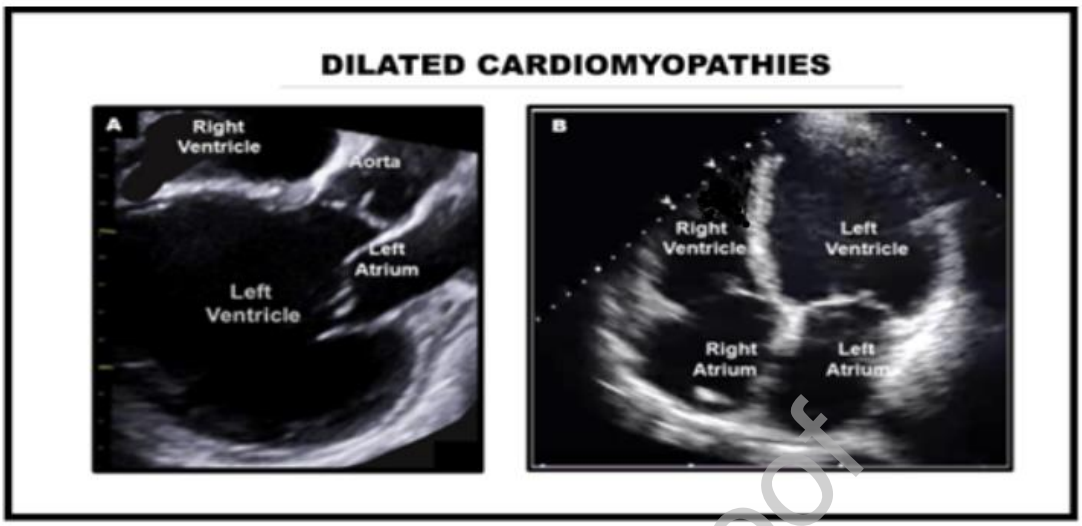

LV mid-wall LGE on cardiac MRI also can be present in DCM but may be absent in up to 65% of individuals with genetically proven DCM disease [76]. In athletes with DCM, a decreased LV ejection fraction is associated with decreased LV strain and an increased burden of ventricular premature contractions [77, 78]. Two echocardiographic measurements that can be useful for predicting and differentiating between athletes with DCM and athletes with LV dilation due solely to endurance exercise are a LV ejection fraction ≤53% and a peak LV global radial strain (GRS) diastolic rate >−1.27 s−1 [77]. GRS represents epicardial muscle fibers, which are affected by the fibrosis present in DCM, in contrast to GLS, which is more representative of subendocardial scarring with ischemic cardiomyopathy.

Epigenetic factors, such as DNA methylation, histone modification, chromatin remodeling, and noncoding RNAs, and acquired modifiers, such as excessive alcohol use, toxic substances, hypertension, and pregnancy can trigger or aggravate DCM. Moreover, between 20% and 35% of individuals with DCM have a family history of DCM which suggests an inherited gene defect [75].

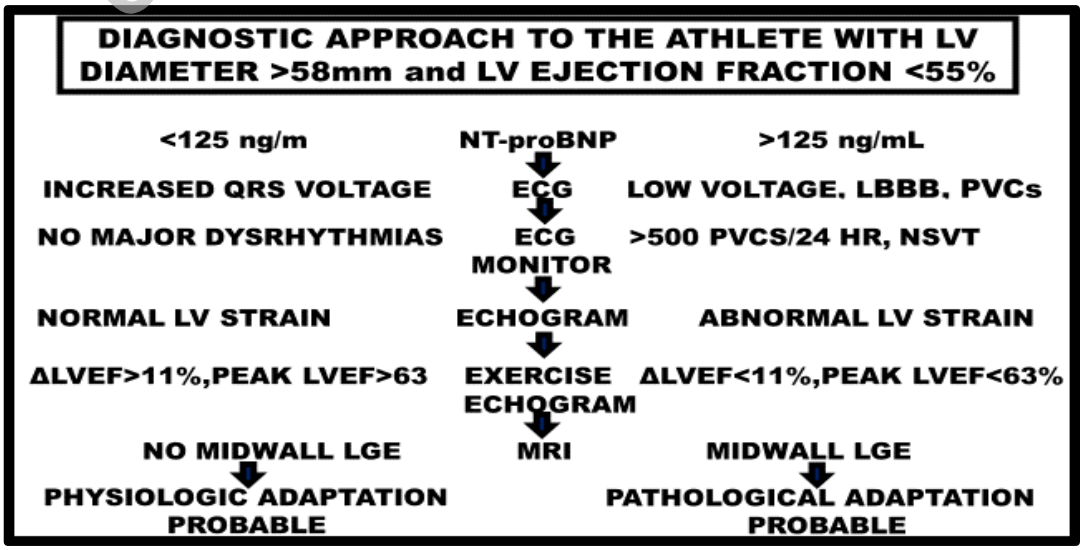

Journal Pre-proof

FIGURE 7 lists an algorithm that is useful in differentiating athletes with DCM from athletes with LV dilatation due to endurance exercise and is adapted in part from [73]. FIGURE 7. Diagnostic Approach to the Athlete with LV Dilation

LBBB: Left Bundle Branch Block; PVCs: Premature Ventricular Contractions, NSVT: Non-sustained Ventricular Tachycardia; ΔLVEF: Change in LV Ejection Fraction; LGE: Late Gadolinium Contrast Enhancement on MRI.

Recently a polygenic risk score (PRS) associated with dilated cardiomyopathy has been reported that has been indexed for the LV end-systolic volume (LVESVi-PRS) and applied to endurance athletes [78]. The PRS is based on the identification of disease-causing variants in protein genes including Lamin A/C, transmembrane protein 43, Desmoplakin, RNA binding motif protein, Phospholamban, and Filamin C truncating variants that have a high risk for cardiomyopathies and cardiac dysrhythmias [79, 80]. Athletes in this study underwent genetic analysis and echocardiographic and cardiac MRI studies. Athletes in the top decile of LVESVi-PRS had an 11-fold increase in the likelihood of decreased LV ejection fraction and an increased risk of developing DCM and cardiac dysrhythmias compared with those in the bottom decile [78]. During a mean follow-up of 4.4 years, two male athletes with decreased LV ejection fractions and increased PRS died suddenly during competition. One death was due to traumatic injury and 1 death was due to sudden cardiac death. Abnormal genetic markers in addition to echocardiographic and MRI imaging markers can identify endurance athletes in whom long-term observation for the development of DCM and cardiac dysrhythmias is appropriate.

Pharmacotherapy is the cornerstone of treatment for DCM in order to reduce mortality, improve functional capacity, prevent heart failure, and recurrent hospitalizations. Treatment with diuretics, an angiotensin-converting enzyme inhibitor (ACE-I) or an angiotensin receptor-neprilysin inhibitor (ARNI), a beta-blocker and a mineralocorticoid receptor antagonist (MRA) reduce symptoms, improve survival, and can reduce the risk of heart failure and hospitalizations in an athlete with DCM [81-83]. Hydralazine and isosorbide dinitrate should be considered in black athletes with LVEF <35% or with an LVEF <45% combined with a dilated left ventricle in NYHA class III-IV despite treatment with an ACE-I (or an angiotensin receptor or neprilysin inhibitor), a beta-blocker and a mineralocorticoid receptor antagonist to reduce symptoms, the risk of heart failure, hospitalization and death [80]. In addition, a sodium-glucose co-transporter 2 inhibitor (SGLT2 inhibitor) is recommended for athletes with DCM and heart failure. Vericiguat may be considered in symptomatic Black and Caucasian athletes with NYHA functional class II-IV who have persistent LV systolic dysfunction despite treatment with an ACE-I (or ARNI), a beta-blocker, a MRA and a SGLT2 inhibitor to decrease symptoms and reduce the risk of heart failure/hospitalization [80].

The indications for an implantable cardiovertor-defibrillator are listed in TABLE 8 and should be thoroughly discussed with the athlete with DCM as well as the athlete's willingness to consistently take medications and restrict exercise. TABLE 8 is Adapted in part from [80].

Journal Pre-proof

TABLE 8: Indications for an implantable cardiovertor/defibrillator (ICD):

ICD-RECOMMENDATIONS FOR SECONDARY PREVENTION:

- **An IDC is recommended to reduce the risk of sudden death and al- cause mortality in athletes with DCM who have survived a cardiac arrest or have recovered from a ventricular dysrhythmia that caused hemodynamic instability**

ICD-RECOMMENDATIONS FOR PRIMARY PREVENTION:

- **An ICD should be considered to reduce the risk of sudden death and all-cause mortality in athletes with DCM, symptomatic heart failure, and LV ejection fraction ≤35% despite >3 months of optimal medical therapy**
- **An ICD should be considered in athletes with DCM with a genotype associated with a high risk for sudden cardiac death and a LV ejection fraction >35% in the presence of non-sustained ventricular tachycardia, increased ventricular ectopic beats, male sex, or significant late gadolinium contrast enhancement on cardiac MRI**
- **An ICD may be considered in selected athletes with DCM with a genotype associated with high sudden cardiac death risk and a LV ejection fraction >35% without additional risk factors.**
- **An ICD may be considered in athletes with DCM without a genotype associated with high sudden cardiac death risk and LV ejection fraction >35% in the presence of additional risk factors (NSVT, increased ventricular ectopic beats, male sex, or significant LGE on cardiac MRI).**

Journal Pre-proof

Athletes with DCM and heart failure with an ECG QRS duration ≥130 msec. should be evaluated for cardiac resynchronization therapy (CRT) with a defibrillator (CRT-D) rather than an ICD alone. Implantable cardioverter defibrillators do reduce mortality in survivors of cardiac arrest and in patients who have experienced sustained symptomatic ventricular dysrhythmias with hemodynamic compromise [81, 82, 84].

ATHLETES WITH ARRHYTHMOGENIC CARDIOMYOPATHY

Arrhythmogenic cardiomyopathy (ACM), is a genetic disorder of the myocardium which causes fatty or fibro-fatty infiltration most commonly in the right ventricular free wall but occasionally in the LV wall. The fatty infiltration causes progressive ventricular dysfunction, with a deterioration in ventricular fractional area change that averages 0.7%/year in the RV, which is associated with a significant risk of ventricular tachycardia, ventricular fibrillation and cardiac arrest [85-86]. Athletes with ACM must be differentiated from elite athletes who participate in sports with high dynamic or mixed sports who can display profound cardiac remodeling that can be confused with ACM [38, 44].

In athletes with ACM, exercise increases the risk of cardiac dysrhythmias and sudden cardiac death by fivefold and ACM is present in as many as 22% of the athletes with sudden cardiac death [3-5]. With ACM, desmosome cardiomyocyte adhesion proteins are defective. As a consequence, ventricular contraction results in cardiomyocyte detachment, cardiomyocyte death, and fibrofatty replacement. Defective cardiomyocyte adhesion proteins plakophilin-2 (PKP2), desmoplakin (DSP), desmoglein-2 (DSG2), and, more rarely, desmocollin-2 (DSC2) and plakoglobin (JUP) and the non-desmosomal myocyte proteins transmembrane protein 43 (TMEM43), desmin (DES), and phospholamin (PLN) are most strongly associated with ACM [87-89]. The defective PKP2 gene and protein accounts for between 20% and 46% of individuals with clinical ACM, whereas DSP and DSG2 account for approximately 10% each, DSC2 accounts for approximately 5%, and JUP (junctional Pkg encoding for Pkg) accounts for <1% [85, 87-89]. Athletes who are carriers of multiple mutations in the same desmosomal gene, or mutations in two or more genes are at significantly greater risk of dysrhythmias than those athletes with a single mutation [90]. The fibrofatty tissue that replaces myocardium in ACM contributes to ventricular dysrhythmias by slowing intraventricular conduction and acting as a macro-reentry mechanism.

The majority of athletes with ACM are diagnosed between the second and fourth decades of life. Male sex is associated with a 1.6- to 3.2-fold relative risk for ACM compared with female sex [91]. The clinical manifestations of ACM include syncope, non-sustained or sustained ventricular tachycardia (VT), and cardiac arrest or sudden cardiac death. Syncope at first presentation is common and is also associated with poor outcomes such as sudden cardiac death [91, 92].

TABLE 9 lists the major and minor criteria for the diagnosis of ACM and is adapted in part from [91, 93, 94]. TABLE 9: Major and Minor Criteria for ACM Diagnosis.

TECHNIQUE	MAJOR CRITERIA	MINOR CRITERA
Transthoracic Echocardlogram	RV Regional akinesia, dyskinesia, or aneurysm + one of the following: PLAX: RVOT ≥32 mm or RVOT/BSA ≥19 mm/m^2 PSAX: RVOT ≥36 mm or RVOT/BSA≥21 mm/m^2 Fractional Area Change ≤33%	RV Regional akinesia, dyskinesia, or aneurysm + one of the following: PLAX: RVOT 29-31 mm or RVOT/BSA 16-18 mm/m^2 PSAX: RVOT 32-35 mm or RVOT/BSA 18-20 mm/m^2 Fractional Area Change 34-40%
Cardiac Magnetic Resonance	RV Regional akinesia, dyskinesia, or aneurysm + one of the following: RV Volume/BSA ≥100 in females and ≥-10 ml/m^2 in males)	RV Regional akinesia, dyskinesia, or aneurysm + one of the following: RV Volume/BSA 90-99 ml/m^2 in females or 100-109 ml/m^2 in males

Journal Pre-proof

	RV Ejection Fraction ≤40%	RV Ejection Fraction 40-44%
ECG	T wave inversion V1-V3 or beyond in athletes age>14 years without cRBBB	T wave inversion V1-V2 in athletes age >14 years without cRBBB; T wave inversion V1-V4 in athletes age >14 with cRBBB
ECG	Epsilon Wave in V1, V2, or V3	>55 msec. terminal QRS activation duration in V1, V2, or V3 without cRBBB
ECG or Rhythm Monitor	Ventricular Tachycardia with LBBB configuration and superior axis in the frontal plane.	Ventricular Tachycardia with LBBB configuration and inferior or indeterminate axis in the frontal plane >500 PVCs/24 hr.
RV Angiography	Regional akinesia, dyskinesia, or aneurysm	
Myocardial Biopsy	<50% RV myocytes with fibrous with or without fatty replacement or <60% RV myocytes.	50-65% RV myocytes with fibrous replacement with or without fatty replacement or 60-75% RV myocytes
Family History	First degree relative with positive ACM criteria or has positive myocardial biopsy for ACM	First degree relative with suspected but not confirmed ACM or sudden death at age<35 years from suspected ACM. Alternatively, second degree relative with positive ACM criteria or has positive myocardial biopsy
Genetics	Pathogenic Mutation of plakophilin-2, desmoplakin , desmoglein-2, desmocollin-2 , plakoglobin, transmembrane protein 43, desmin, or phospholamin	

PLAX: Parasternal Long Axis Echocardiographic View; PLAS: Parasternal Short Axis View; RVOT: Right Ventricular Outflow Tract; BSA: Body Surface Area; cRBBB: Complete Right Bundle Branch Block; LBBB: Left Bundle Branch Block; RV: Right Ventricle.

Journal Pre-proof

A Definite Diagnosis is present with 2 Major or 1 Major + 2 Minor or 4 Minor Criteria in different categories. A Borderline Diagnosis is present with 1 Major + 1 Minor or 3 Minor Criteria in different categories. A Possible Diagnosis is present with 1 Major or 2 Minor Criteria. The major criteria are associated with 68% to 76% sensitivity and 90% to 98% specificity for diagnosing ACM, whereas the minor criteria have 79% to 89% sensitivity and 85% to 97% specificity for ACM [93].

Transesophageal echocardiography can provide additional diagnostic information for ACM, such as RV bulges, RV sacculations, aneurysms with or without thrombus, partial or complete loss of RV trabeculations, and hypertrophy of the RV moderator band.

FIGURE 9 illustrates an echocardiogram from an athlete with ACM with a significant increase in the RV with a volume greater than 110mL/m^2 and an increase in the right atrium as seen on the apical four chamber echocardiographic view (Panel A) and an increase in the RV outflow tract diameter that exceeds 32 mm and $\geq$19 mm/m^2 in the parasternal long axis view (Panel B). FIGURE 9.

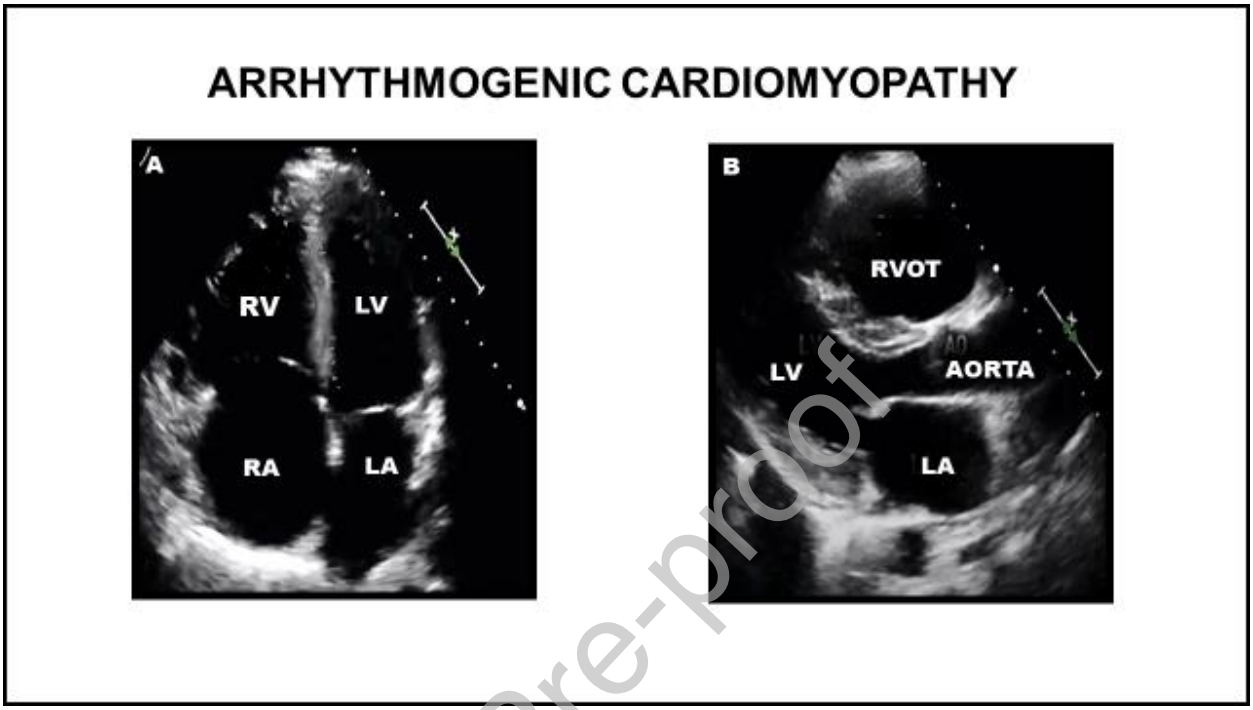

In FIGURE 9, RV: Right Ventricle, LV: Left Ventricle, RVOT: Right Ventricular Outflow Tract, RA: Right Atrium, LA: Left Atrium. FIGURE 9 is courtesy of the General Hospital.

Athletes diagnosed with ACM should undergo genetic testing for pathologic myocyte gene mutations. If a pathogenic mutation is identified, selected testing for the pathogenic mutation should be performed in first degree relatives in order to identify those relatives at risk for development of ACM. If the pathogenic mutation is identified in a family member, cardiac evaluation including an ECG, Holter monitor or patch/loop recorder and echocardiogram or MRI should be performed in those individuals. If no pathogenic mutation is identified, cardiac testing should be performed in all first degree family members every 2 to 3 years thereafter [90].

There can be significant overlap between athletes with ACM and athletes with physiologic cardiac dilation. High intensity and endurance exercise can provoke in athletes RV dilation and reduction in ejection fractions. Recently, a ratio of RV inflow dimension in the apical view and the LV end-diastolic dimension in the parasternal long-axis view greater than 0.9 has been proposed as a cutoff to differentiate physiological from pathological ACM remodeling in the athlete [34, 39]. In addition, RV myocardial wall motion and RV strain are usually preserved in athletes with physiologic ventricular dilation in contrast to the athlete with ACM where RV myocardial wall motion and RV strain are abnormal. Furthermore, mitral valvular regurgitation and myocardial akinesia or dyskinesia are absent

Journal Pre-proof

in the athlete with physiologic remodeling. There is also less propensity for gadolinium contrast uptake on MRI in athletes with ventricular dilation due solely to endurance exercise where gadolinium contrast uptake may occur at the RV insertion points in the interventricular septum [34, 38, 39].

In asymptomatic athletes who are ACM gene carriers, exercise stress testing can unmask latent pathologic changes such as increased terminal duration of the ECG QRS complex, an ECG epsilon wave, premature ventricular depolarizations, non-sustained ventricular tachycardia and no change or a decrease in the ventricular ejection fractions with exercise [95]. In doubtful cases, cardiac MRI can provide an accurate structural and functional RV evaluation by distinguishing RV segments with akinesia or dyskinesia, late gadolinium enhancement in the free ventricular wall due to fibrosis, or RV outflow tract microaneurysms.

Risk stratification should be promptly carried out when a diagnosis of ACM is made. Risk factors predictive of ventricular dysrhythmias and sudden cardiac death include age of onset, male sex, specific genetic mutation(s), cardiac syncope, history of ventricular dysrhythmias, degree of fatty or fibrofatty myocardial involvement, and history of high intensity or endurance exercise routine. An international collaboration has derived a risk calculator for the prediction of sustained ventricular dysrhythmias, ventricular fibrillation or cardiac arrest/sudden cardiac death in individuals with definite ACM [96, 97]. On the basis of components of age at diagnosis, sex, cardiac syncope, extent of ECG T wave inversion, 24-hour premature ventricular complex count, history of non-sustained ventricular tachycardia, and the RV ejection fraction, a 5-year risk score can be obtained. The calculator of the ACM risk score is available at http://ACMrisk.com [96, 97, 98].

TREATMENT

Restriction of exercise activity is extremely important in the management of individuals with ACM because restriction of exercise intensity and duration significantly decreases the amount of ventricular dysrhythmias. Athletes with ACM should be restricted to low level activity such as 30 minutes of brisk walking per day, because exercise levels >650 MET-hours per year accelerate the phenotypic expression of ACM [99-101]. Exercise restriction should also be advised in athletes and in family members who are genotype positive but phenotype negative in order to delay potential phenotypic expression and should also be considered in athletes with borderline or possible ACM [91,102, 103].

The use of beta-adrenergic receptor antagonists is recommended in athletes with ACM and non-sustained ventricular tachycardia or other ventricular dysrhythmias [91]. Adjuvant pharmacotherapy with flecainide or amiodarone should be considered in athletes with ongoing ventricular dysrhythmias despite the use of a beta-adrenergic receptor antagonist [104]. However, therapy with beta adrenergic receptor antagonists, flecainide, amiodarone or ventricular ablation of endocardial/epicardial ventricular tachycardia foci does not obviate the need for ICDs in high risk athletes as determined by the ACM risk score [91, 99, 105, 106]. For athletes with asymptomatic but significant RV and/or LV

Journal Pre-proof

reduction in ejection fractions, treatment with angiotensin-converting-enzyme inhibitors or angiotensin II receptor blockers should also be considered [99].

The decision to insert an ICD in an athlete for primary preventions requires thorough evaluation of the risk of sudden cardiac death and the risk of ICD device-related complications, which include a 3.9% annual rate of shocks and a 4.2% annual rate of complications such as infection or lead malfunction [107].. In those athletes with a 5% to 15% 5-year risk with a history of aborted cardiac arrest or sudden cardiac death, sustain ventricular tachycardia, severe RV, LV or biventricular dysfunction, an ICD is indicated [99, 108, 109]. In those athletes with intermediate risk with ≥1 major risk factor such as syncope, non-sustain ventricular tachycardia, moderate ventricular dysfunction, an ICD should be considered. In those athletes with ≥I minor risk factors, an ICD may be considered and in those athletes with <5% 5-year risk, an ICD is not recommended [99, 108, 109]. For athletes undergoing ICD implantation for primary prevention of ventricular dysrhythmias, a subcutaneous ICD should be considered whereas for athletes who present with sustained monomorphic VT, an endocardial ICD device should be considered because of the risk of recurrent sustained dysrhythmias. Finally, athletes with uncontrollable ventricular tachydysrhythmias or intractable heart failure require evaluation for heart transplantation [110].

Athletes with ACM require reevaluation every one to two years for new onset or worsening of symptoms, progression of ventricular myocardial abnormalities, and supraventricular and ventricular dysrhythmias. In these athletes, the risk of sudden cardiac arrest/death should be re-assessed and treatment further optimized [99].

ATHLETES WITH IMPLANTABLE CARDIOVERTERS-DEFIBRILLATORS (ICDs)

In individuals of all ages with cardiac disease at high risk for ventricular dysrhythmias, ICDs are effective in preventing ventricular dysrhythmias and sudden cardiac arrest [84, 107-109, 111-113]. However in the past the AHA/ACC guidelines have recommended against all moderate and high-intensity sports for athletes with ICDs because the safety and efficacy of these devices during sport competition was unknown. Recently, studies have reported that athletes primarily with HCM or long QT syndrome with LV ejection fractions in the normal or the mildly reduced range may be able to participate safely in noncontact or low contact competitive sports with a low risk of life-threatening events [113-116]. In these studies appropriate, as well as inappropriate shocks due to T-wave over-sensing, supraventricular or sinus tachycardia, and lead malfunction, have been reported. A limitation of some of these studies is that ICD shocks have been self-reported by the athletes or their care givers and these individuals may have purposefully withheld information about ICD shocks in order to continue sports participation. Nevertheless, the AHA/ACC currently has Class II recommendations for athletes with ICDs where participation in sports may be considered if the risk of adverse outcomes appears to be low or disease-specific management may reduce the risk to acceptable levels [117,118].

Journal Pre-proof

In addition, the European Association of Preventive Cardiology recommends that return to play decisions be made after thorough discussion and shared decision making by the physician(s) with the athlete with the ICD, the interested parties (care providers, coaches, institutions and/or organizations) of the "four Ds": (1) the underlying cardiac disease; (2) the danger to the athlete, third parties involved, and the environment; (3) the device; and (4) the risk of dysrhthymias or ICD shocks [119].

When significant debate or doubt occurs regarding the participation of an athlete with an ICD in competitive sports, consultation should be obtained from medical experts in sports medicine, cardiomyopathies and ICDs. In athletes where a consensus decision is made that return to play is desirable and permissible, maximal effort exercise testing should be performed to evaluate for inducible dysrhythmias prior to sports participation and the treatment of the athlete adjusted if necessary [120].

Athletes with ICDs who do participate in competitive sports often require optimal device-based tachycardia programming, such as high-rate tachycardia cutoff (200 beats per minute) and long-detection duration programming [121]. Optimal ICD programing reduces the total and inappropriate ICD shocks without decreasing athlete survival or increasing the risk of transient loss-of-consciousness. A remote ICD monitoring plan and an emergency action plan for cardiac events also should be developed. In addition, the National Collegiate Athletic Association in conjunction with the American College of Cardiology recommends the presence at sporting events of responders trained in cardiopulmonary resuscitation and automatic external defibrillator (AED) use, immediate access to defibrillation devices by sport personnel, and the integration of onsite sport personnel responders with local emergency medical services [122].

All athletes with ICDs must be carefully followed-up by a physician with prompt intervention when new/novel symptoms occur or worsening of the underlying heart disease occurs. In addition, ongoing assessment by a physician of the psychologic needs of the athlete with an ICD is an important component of management. Athlete anxiety and depression can significantly increase after a single or multiple ICD shocks [123,124].

Journal Pre-proof

SUMMARY AND CONCLUSIONS

There are currently 5 million active high school, collegiate, professional, and master athletes in the United States. Regular intense exercise by these athletes can promote structural, electrical and functional remodeling of the hearts termed the "athlete's heart." Regular intense exercise by an athlete can also lead to pathological adaptions that can promote or worsen cardiac disease. Physicians must therefore be aware of the normal cardiac anatomy and physiology of the athlete, the differentiation of the normal athlete heart from the athlete with cardiomyopathy, and the contemporary care of the athlete with cardiomyopathy. The distinction between physiologic changes and pathologic

changes in the hearts of athletes has important prognostic and therapeutic implications. Failure by the physician to correctly diagnose an athlete with hypertrophic cardiomyopathy, dilated cardiomyopathy, or arrhythmogenic right ventricular cardiomyopathy can lead to sudden cardiac arrest and death in an athlete during training or competition. Furthermore, an incorrect diagnosis by a physician of cardiac pathology in an athlete can lead to an unnecessary restriction of athlete training and competition with resultant significant athlete emotional, psychological, financial, and long-term health consequences. All athletes with cardiomyopathies must be carefully followed by a physician with prompt intervention when new/novel symptoms occur or worsening of the underlying heart disease occurs.

ACKNOWLEDGEMENT:

The Author thanks Ms. Meg Blount, MLIS and all the librarians at the Moffitt Hospital/University of South Florida for their assistance in providing many of the articles cited in this manuscript. The Author also thanks the General Hospital Electrocardiographic and Echocardiographic Departments for their contributions to this article.

COMPLIANCE WITH ETHICAL STANDARDS.

The author has no potential conflicts of interest. This is a Review Article. No human studies or animal studies were carried out by the author for this article.

ETHICAL APPROVAL: This article does not contain any studies with humans or with animals performed by the author.

FINANCIAL & COMPETING INTERESTS DISCLOSURE: Work in the cardiovascular research laboratory of the Author is supported by a grant from the Cardiomyopathy Foundation. The author has no other relevant affiliations and no financial involvement with any organization or entity with a financial interest in or financial conflict with the subject matter or materials discussed in the manuscript. No writing assistance was utilized in the production of this manuscript

Journal Pre-proof

BIBLIOGRAPHY. Due to space limitations, not every pertinent article could be included in the Bibliography

1. La Gerche A, Wasfy MM, Brosnan MJ, Claessen G, Fatkin D, Heidbuchel H, Baggish AL, Kovacic JC. The Athlete's Heart-Challenges and Controversies: JACC Focus Seminar 4/4. J Am Coll Cardiol. 2022;80(14):1346-1362. doi: 10.1016/j.jacc.2022.07.014 x

2. Maron BJ, Carney KP, Lever HM, Lewis JF, Barac I, Casey SA, Sherrid MV. Relationship of race to sudden cardiac death in competitive athletes with hypertrophic cardiomyopathy. J Am Coll Cardiol. 2003;41(6):974-80. doi: 10.1016/s0735-1097(02)02976-5

3. Harmon KG, Asif IM, Maleszewski JJ, Owens DS, Prutkin JM, Salerno JC, Zigman ML, Ellenbogen R, Rao AL, Ackerman MJ, Drezner JA. Incidence, Cause, and Comparative Frequency of Sudden Cardiac Death in National Collegiate Athletic Association Athletes: A Decade in Review. Circulation. 2015;132(1):10-9. doi: 10.1161/CIRCULATIONAHA.115.015431

4.Peterson DF, Kucera K, Thomas LC, et al. Aetiology and incidence of sudden cardiac arrest and death in young competitive athletes in the USA: a 4-year prospective study. Br J Sports Med. 2021;55(21):1196–1203. doi.10.1136/ bjsports-2020-102666;

5. Maron BJ, Doerer JJ, Haas TS, Tierney DM, Mueller FO. Sudden deaths in young competitive athletes: analysis of 1866 deaths in the United States, 1980-2006. Circulation. 2009; 119(8):1085-92. doi: 10.1161/CIRCULATIONAHA.108.804617

6. Prutkin JM, Salerno JC, Zigman ML, Ellenbogen R, Rao AL, Ackerman MJ, Drezner JA. Incidence, Cause, and Comparative Frequency of Sudden Cardiac Death in National Collegiate Athletic Association Athletes: A Decade in Review. Circulation. 2015;132(1):10-9. doi: 10.1161/ CIRCULATIONAHA.115.015431

7. Maron BJ, Levine BD, Washington RL, Baggish AL, Kovacs RJ, Maron MS. Eligibility and Disqualification Recommendations for Competitive Athletes With Cardiovascular Abnormalities: Task Force 2: Preparticipation Screening for Cardiovascular Disease in Competitive Athletes: A Scientific Statement From the American Heart Association and American College of Cardiology. J Am Coll Cardiol. 2015;66(21):2356-2361. doi: 10.1016/j.jacc.2015.09.034.

8. Siebert DM, Drezner JA. Detection and Management of Heart Disease in Athletes. Prim Care. 2020;47(1):19-35. doi: 10.1016/j.pop.2019.11.001

9. Morganroth J, Maron BJ, Henry WL, Epstein SE. Comparative left ventricular dimensions in trained athletes. Ann Intern Med. 1975;82:521–524.

10. Morganroth J, Maron BJ. The athlete's heart syndrome: a new perspective. Ann N Y Acad Sci. 1977;301:931-941. doi: 10.1111/j.1749-6632.1977.tb38259.x.

11. Barbieri A, Bursi F, Camaioni G, Maisano A, Imberti JF, Albini A, De Mitri G, Mantovani F, Boriani G. Echocardiographic Left Ventricular Mass Assessment: Correlation between 2D-Derived Linear Dimensions and 3-Dimensional Automated, Machine Learning-Based Methods in Unselected Patients. J Clin Med. 2021;10(6):1279. doi: 10.3390/jcm10061279.

12. Prior DL, La Gerche A. The athlete's heart. Heart. 2012;98(12):947-55. doi: 10.1136/heartjnl-2011-301329.

13. Baggish AL, Battle RW, Beckerman JG, Bove AA, Lampert RJ, Levine BD, Link MS, Martinez MW, Molossi SM, Salerno J, Wasfy MM, Weiner RB, Emery MS; ACC's Sports and Exercise Council Leadership Group. J Am Coll Cardiol. 2017;70(15):1902-1918. doi: 10.1016/j.jacc.2017.08.0 5

14. Baggish AL, Battle RW, Beaver TA, Border WL, Douglas PS, Kramer CM, Martinez MW, Mercandetti JH, Phelan D, Singh TK, Weiner RB, Williamson E. Recommendations on the Use of Multimodality Cardiovascular Imaging in Young Adult Competitive Athletes: A Report from the American Society of Echocardiography in Collaboration with the Society of Cardiovascular Computed Tomography and the Society for Cardiovascular Magnetic Resonance. J Am Soc Echocardiogr. 2020;33(5):523-549. doi: 10.1016/j.echo.2020.02.009

15. Sharma S, Drezner JA, Baggish A, Papadakis M, Wilson MG, Prutkin JM, La Gerche A, Ackerman MJ, Borjesson M, Salerno JC, Asif IM, Owens DS, Chung EH, Emery MS, Froelicher VF, Heidbuchel H, Adamuz C, Asplund CA, Cohen G, Harmon KG, Marek JC, Molossi S, Niebauer J, Pelto HF, Perez MV, Riding NR, Saarel T, Schmied CM, Shipon DM, Stein R, Vetter VL, Pelliccia A, Corrado D. International recommendations for electrocardiographic interpretation in athletes. Eur Heart J. 2018;39(16):1466-1480. doi: 10.1093/eurheartj/ehw631.

16. Drezner JA, Sharma S, Baggish A, Papadakis M, Wilson MG, Prutkin JM, Gerche A, Ackerman MJ, Borjesson M, Salerno JC, Asif IM, Owens DS, Chung EH, Emery MS, Froelicher VF, Heidbuchel H, Adamuz C, Asplund CA, Cohen G, Harmon KG, Marek JC, Molossi S, Niebauer J, Pelto HF, Perez MV, Riding NR, Saarel T, Schmied CM, Shipon DM, Stein R, Vetter VL, Pelliccia A, Corrado D. International criteria for electrocardiographic interpretation in athletes: Consensus statement. Br J Sports Med. 2017;51(9):704-731. doi: 10.1136/bjsports-2016-097331

Journal Pre-proof

17. Zaidi A, Ghani S, Sheikh N, Gati S, Bastiaenen R, Madden B, Papadakis M, Raju H, Reed M, Sharma R, Behr ER, Sharma S. Clinical significance of electrocardiographic right ventricular hypertrophy in athletes: comparison with arrhythmogenic right ventricular cardiomyopathy and pulmonary hypertension. Eur Heart J. 2013;34(47):3649-56. doi: 10.1093/eurheartj/eht391

18. Papadakis M, Basavarajaiah S, Rawlins J, Edwards C, Makan J, Firoozi S, Carby L, Sharma S. Prevalence and significance of T-wave inversions in predominantly Caucasian adolescent athletes. Eur Heart J. 2009;30(14):1728-35. doi: 10.1093/eurheartj/ehp164.

19. Papadakis M, Carre F, Kervio G, Rawlins J, Panoulas VF, Chandra N, Basavarajaiah S, Carby L, Fonseca T, Sharma S. The prevalence, distribution, and clinical outcomes of electrocardiographic repolarization patterns in male athletes of African/Afro-Caribbean origin. Eur Heart J. 2011;32(18):2304-13. doi: 10.1093/eurheartj/ehr140

20. Sheikh N, Papadakis M, Schnell F, Panoulas V, Malhotra A, Wilson M, Carré F, Sharma S. Clinical Profile of Athletes With Hypertrophic Cardiomyopathy. Circ Cardiovasc Imaging. 2015;8(7):e003454. doi: 10.1161/CIRCIMAGING.114.003454

21. Brosnan MJ, Rakhit D. Differentiating Athlete's Heart From Cardiomyopathies - The Left Side. Heart Lung Circ. 2018;27(9):1052-1062. doi: 10.1016/j.hlc.2018.04.297

22. Gati S, Sheikh N, Ghani S, Zaidi A, Wilson M, Raju H, Cox A, Reed M, Papadakis M, Sharma S. Should axis deviation or atrial enlargement be categorised as abnormal in young athletes? The athlete's electrocardiogram: time for re-appraisal of markers of pathology. Eur Heart J. 2013;34(47):3641-8. doi: 10.1093/eurheartj/eht390

23. Pelliccia A, Culasso F, Di Paolo FM, Accettura D, Cantore R, Castagna W, Ciacciarelli A, Costini G, Cuffari B, Drago E, Federici V, Gribaudo CG, Iacovelli G, Landolfi L, Menichetti G, Atzeni UO, Parisi A, Pizzi AR, Rosa M, Santelli F, Santilio F, Vagnini A, Casasco M, Di Luigi L. Prevalence of abnormal electrocardiograms in a large, unselected population undergoing pre-participation cardiovascular screening. Eur Heart J. 2007;28(16):2006-10. doi: 10.1093/eurheartj/ehm219.

24. Kim JH, Noseworthy PA, McCarty D, Yared K, Weiner R, Wang F, Wood MJ, Hutter AM, Picard MH, Baggish AL. Significance of electrocardiographic right bundle branch block in trained athletes. Am J Cardiol. 2011;107(7):1083-9. doi: 10.1016/j.amjcard.2010.11.037.

25. Marcus FI, McKenna WJ, Sherrill D, Basso C, Bauce B, Bluemke DA, Calkins H, Corrado D, Cox MG, Daubert JP, Fontaine G, Gear K, Hauer R, Nava A, Picard MH, Protonotarios N, Saffitz JE, Sanborn DM, Steinberg JS, Tandri H, Thiene G, Towbin JA, Tsatsopoulou A, Wichter T, Zareba W. Diagnosis of arrhythmogenic right ventricular cardiomyopathy/dysplasia: proposed modification of the task force criteria. Circulation. 2010;121(13):1533-41. doi: 10.1161/CIRCULATIONAHA.108.840827.

26. Platonov PG, Svensson A. Epsilon Waves as an Extreme Form of Depolarization Delay: Focusing on the Arrhythmogenic Right Ventricular Cardiomyopathy/Dysplasia. Curr Cardiol Rev. 2021;17(1):17-23. doi: 10.2174/1573403X16666200810105029. PMID: 32778035

27. Riding NR, Sheikh N, Adamuz C, Watt V, Farooq A, Whyte GP, George KP, Drezner JA, Sharma S, Wilson MG. Comparison of three current sets of electrocardiographic interpretation criteria for use in screening athletes. Heart. 2015;101(5):384-90. doi: 10.1136/heartjnl-2014-306437

28. Rowin EJ, Maron BJ, Appelbaum E, Link MS, Gibson CM, Lesser JR, Haas TS, Udelson JE, Manning WJ, Maron MS. Significance of false negative electrocardiograms in preparticipation screening of athletes for hypertrophic cardiomyopathy. Am J Cardiol. 2012;110(7):1027-32. doi: 10.1016/j.amjcard.2012.05.035.

Journal Pre-proof

29. Venckunas T, Lionikas A, Marcinkeviciene JE, Raugaliene R, Alekrinskis A, Stasiulis A. Echocardiographic parameters in athletes of different sports. J Sports Sci Med. 2008;7(1):151-6.

30. D'Ascenzi F, Pelliccia A, Solari M, Piu P, Loiacono F, Anselmi F, Caselli S, Focardi M, Bonifazi M, Mondillo S. Normative Reference Values of Right Heart in Competitive Athletes: A Systematic Review and Meta-Analysis. J Am Soc Echocardiogr. 2017;30(9):845-858.e2. doi: 10.1016/j.echo.2017.06.013

31. Oxborough D, Augustine D, Gati S, George K, Harkness A, Mathew T, Papadakis M, Ring L, Robinson S, Sandoval J, Sarwar R, Sharma S, Sharma V, Sheikh N, Somauroo J, Stout M, Willis J, Zaidi A. A guideline update for the practice of echocardiography in the cardiac screening of sports participants: a joint policy statement from the British Society of Echocardiography and Cardiac Risk in the Young. Echo Res Pract. 2018;5(1):G1-G10. doi: 10.1530/ERP-17-0075.

32. Vinereanu D, Florescu N, Sculthorpe N, Tweddel AC, Stephens MR, Fraser AG. Differentiation between pathologic and physiologic left ventricular hypertrophy by tissue Doppler assessment of long-axis function in patients with hypertrophic cardiomyopathy or systemic hypertension and in athletes. Am J Cardiol. 2001;88(1):53-8. doi: 10.1016/s0002-9149(01)01585- Oxborough

33. Flanagan H, Cooper R, George KP, Augustine DX, Malhotra A, Paton MF, Robinson S, Oxborough D. The athlete's heart: insights from echocardiography. Echo Res Pract. 2023;10(1):15. doi: 10.1186/s44156-023-00027-8.

34. Niederseer D, Rossi VA, Kissel C, Scherr J, Caselli S, Tanner FC, Bohm P, Schmied C. Role of echocardiography in screening and evaluation of athletes. Heart. 2020:heartjnl-2020-317996. doi: 10.1136/heartjnl-2020-317996

35. Pelliccia A, Maron BJ, De Luca R, Di Paolo FM, Spataro A, Culasso F. Remodeling of left ventricular hypertrophy in elite athletes after long-term deconditioning. Circulation. 2002;105(8):944-9. doi: 10.1161/hc0802.104534.

36. Finocchiaro G, Dhutia H, D'Silva A, Malhotra A, Steriotis A, Millar L, Prakash K, Narain R, Papadakis M, Sharma R, Sharma S. Effect of Sex and Sporting Discipline on LV Adaptation to Exercise. JACC Cardiovasc Imaging. 2017;10(9):965-972. doi: 10.1016/j.jcmg.2016.08.011

37. D'Ascenzi F, Pisicchio C, Caselli S, Di Paolo FM, Spataro A, Pelliccia A. RV Remodeling in Olympic Athletes. JACC Cardiovasc Imaging. 2017;10(4):385-393. doi: 10.1016/j.jcmg.2016.03.017 |

38. Danielian A, Shah AB. Differentiating Physiology from Pathology: The Gray Zones of the Athlete's Heart. Clin Sports Med. 2022;41(3):425-440. doi: 10.1016/j.csm.2022.02.005

39. Pelliccia A, Caselli S, Sharma S, Basso C, Bax JJ, Corrado D, D'Andrea A, D'Ascenzi F, Di Paolo FM, Edvardsen T, Gati S, Galderisi M, Heidbuchel H, Nchimi A, Nieman K, Papadakis M, Pisicchio C, Schmied C, Popescu BA, Habib G, Grobbee D, Lancellotti P; Internal reviewers for EAPC and EACVI. European Association of Preventive Cardiology (EAPC) and European Association of Cardiovascular Imaging (EACVI) joint position statement: recommendations for the indication and interpretation of cardiovascular imaging in the evaluation of the athlete's heart. Eur Heart J. 2018;39(21):1949-1969. doi: 10.1093/eurheartj/ehx532.

40. D'Andrea A, Cocchia R, Riegler L, Scarafile R, Salerno G, Gravino R, Golia E, Pezzullo E, Citro R, Limongelli G, Pacileo G, Cuomo S, Caso P, Russo MG, Bossone E, Calabrò R. Left ventricular myocardial velocities and deformation indexes in top-level athletes. J Am Soc Echocardiogr. 2010;23(12):1281-8. doi: 10.1016/j.echo.2010.09.020

41. Fábián A, Ujvári A, Tokodi M, Lakatos BK, Kiss O, Babity M, Zámodics M, Sydó N, Csulak E, Vágó H, Szabó L, Kiss AR, Szűcs A, Hizoh I, Merkely B, Kovács A. Biventricular mechanical pattern of the

Journal Pre-proof

athlete's heart: comprehensive characterization using three-dimensional echocardiography. Eur J Prev Cardiol. 2022;29(12):1594-1604. doi: 10.1093/eurjpc/zwac026

42. Radmilovic J, D'Andrea A, D'Amato A, Tagliamonte E, Sperlongano S, Riegler L, Scarafile R, Forni A, Muscogiuri G, Pontone G, Galderisi M, Russo MG. Echocardiography in Athletes in Primary Prevention of Sudden Death. J Cardiovasc Echogr. 2019;29(4):139-148. doi: 10.4103/jcecho.jcecho_26_19;

43. Millar LM, Fanton Z, Finocchiaro G, Sanchez-Fernandez G, Dhutia H, Malhotra A, Merghani A, Papadakis M, Behr ER, Bunce N, Oxborough D, Reed M, O'Driscoll J, Tome Esteban MT, D'Silva A, Carr-White G, Webb J, Sharma R, Sharma S. Differentiation between athlete's heart and dilated cardiomyopathy in athletic individuals. Heart. 2020;106(14):1059-1065. doi: 10.1136/heartjnl-2019-316147.

44. Martinez MW, Kim JH, Shah AB, Phelan D, Emery MS, Wasfy MM, Fernandez AB, Bunch TJ, Dean P, Danielian A, Krishnan S, Baggish AL, Eijsvogels TMH, Chung EH, Levine BD. Exercise-Induced Cardiovascular Adaptations and Approach to Exercise and Cardiovascular Disease: JACC State-of-the-Art Review. J Am Coll Cardiol. 2021 Oct 5;78(14):1453-1470. doi: 10.1016/j.jacc.2021.08.003.

45. Małek ŁA, Mazurkiewicz Ł, Marszałek M, Barczuk-Falęcka M, Simon JE, Grzybowski J, Miłosz-Wieczorek B, Postuła M, Marczak M. Deformation Parameters of the Heart in Endurance Athletes and in Patients with Dilated Cardiomyopathy-A Cardiac Magnetic Resonance Study. Diagnostics (Basel). 2021;11(2):374. doi: 10.3390/diagnostics11020374

46. Oxborough D, Sharma S, Shave R, Whyte G, Birch K, Artis N, Batterham AM, George K. The right ventricle of the endurance athlete: the relationship between morphology and deformation. J Am Soc Echocardiogr. 2012;25(3):263-71. doi: 10.1016/j.echo.2011.11.017.

47. Bohm P, Schneider G, Linneweber L, Rentzsch A, Kramer N, Abdul-Khaliq H, Kindermann W, Meyer T, Scharhag J. Right and left ventricular function and mass in male elite master athletes: a controlled contrast-enhanced cardiovascular magnetic resonance study. Circulation 2016;133:1927–1935.

48. Christou GA, O'Driscoll JM. The impact of demographic, anthropometric and athletic characteristics on left atrial size in athletes. Clin Cardiol. 2020;43(8):834-842. doi: 10.1002/clc.23368.

49. Iskandar A, Mujtaba MT, Thompson PD. Left Atrium Size in Elite Athletes. JACC Cardiovasc Imaging. 2015l;8(7):753-62. doi: 10.1016/j.jcmg.2014.12.032.

50. D'Ascenzi F, Anselmi F, Focardi M, Mondillo S. Atrial Enlargement in the Athlete's Heart: Assessment of Atrial Function May Help Distinguish Adaptive from Pathologic Remodeling. J Am Soc Echocardiogr. 2018;31(2):148-157. doi: 10.1016/j.echo.2017.11.009.

51. Sanchis-Gomar F, Garatachea N, Catalán P, López-Ramón M, Lucia A, Serrano-Ostáriz E. LA Size in Former Elite Athletes. JACC Cardiovasc Imaging. 2016;9(5):630-632.

52. Sanz-de la Garza M, Carro A, Caselli S. How to interpret right ventricular remodeling in athletes. Clin Cardiol. 2020;43(8):843-851. doi: 10.1002/clc.23350

53. George K, Whyte GP, Green DJ, Oxborough D, Shave RE, Gaze D, Somauroo J. The endurance athletes heart: acute stress and chronic adaptation. Br J Sports Med. 2012;46 Suppl 1:i29-36. doi: 10.1136/bjsports-2012-091141.

54. Biffi A, Pelliccia A, Verdile L, Fernando F, Spataro A, Caselli S, Santini M, Maron BJ. Long-term clinical significance of frequent and complex ventricular tachyarrhythmias in trained athletes. J Am Coll Cardiol. 2002;40(3):446-52. doi: 10.1016/s0735-1097(02)01977-0

Journal Pre-proof

55 Maron BJ. Distinguishing hypertrophic cardiomyopathy from athlete's heart: a clinical problem of increasing magnitude and significance. Heart. 2005;91(11):1380-2. doi: 10.1136/hrt.2005.060962

56. Paterick TE, Gordon T, Spiegel D. Echocardiography: profiling of the athlete's heart. J Am Soc Echocardiogr. 2014;27(9):940-8. doi: 10.1016/j.echo.2014.06.008

57. Ommen SR, Mital S, Burke MA, Day SM, Deswal A, Elliott P, Evanovich LL, Hung J, Joglar JA, Kantor P, Kimmelstiel C, Kittleson M, Link MS, Maron MS, Martinez MW, Miyake CY, Schaff HV, Semsarian C, Sorajja P. 2020 AHA/ACC Guideline for the Diagnosis and Treatment of Patients With Hypertrophic Cardiomyopathy: Executive Summary: A Report of the American College of Cardiology/American Heart Association Joint Committee on Clinical Practice Guidelines. Circulation. 2020;142(25):e533-e557. doi: 10.1161/CIR.0000000000000938.

58. Sheikh N, Papadakis M, Schnell F, Panoulas V, Malhotra A, Wilson M, Carré F, Sharma S. Clinical Profile of Athletes With Hypertrophic Cardiomyopathy. Circ Cardiovasc Imaging. 2015l;8(7):e003454. doi: 10.1161/CIRCIMAGING.114.003454

59. D'Andrea A, Caso P, Cuomo S, Salerno G, Scarafile R, Mita C, De Corato G, Sarubbi B, Scherillo M, Calabrò R. Prognostic value of intra-left ventricular electromechanical asynchrony in patients with mild hypertrophic cardiomyopathy compared with power athletes. Br J Sports Med. 2006;40(3):244-50; discussion 244-50. doi: 10.1136/bjsm.2005.022194.

60. Maron BJ. Sudden death in young athletes. N Engl J Med 2000;349:1064–75.

61. Mitevks IP. Focus on echocardiography in hypertrophic cardiomyopathy. e-Journal of Cardiology Practice 2015; 13;N° 20

62. Gabrielli L, Enríquez A, Córdova S, Yáñez F, Godoy I, Corbalán R. Assessment of left atrial function in hypertrophic cardiomyopathy and athlete's heart: a left atrial myocardial deformation study. Echocardiography. 2012;29(8):943-9. doi: 10.1111/j.1540-8175.2012.01719.x.

63.Radmilovic J, D'Andrea A, D'Amato A, Tagliamonte E, Sperlongano S, Riegler L, Scarafile R, Forni A, Muscogiuri G, Pontone G, Galderisi M, Russo MG. Echocardiography in Athletes in Primary Prevention of Sudden Death. J Cardiovasc Echogr. 2019;29(4):139-148. doi: 10.4103/jcecho.jcecho_26_19

64. Liu H, Pozios I, Haileselassie B, Nowbar A, Sorensen LL, Phillip S, Lu DY, Ventoulis I, Luo H, Abraham MR, Abraham TP. Role of Global Longitudinal Strain in Predicting Outcomes in Hypertrophic Cardiomyopathy. Am J Cardiol. 2017;120(4):670-5

65. Małek ŁA, Bucciarelli-Ducci C Myocardial fibrosis in athletes-Current perspective. Clin Cardiol. 2020;43(8):882-888. doi: 10.1002/clc..23360.

66. Zorzi A, Perazzolo Marra M, Rigato I, De Lazzari M, Susana A, Niero A, Pilichou K, Migliore F, Rizzo S, Giorgi B, De Conti G, Sarto P, Serratosa L, Patrizi G, De Maria E, Pelliccia A, Basso C, Schiavon M, Bauce B, Iliceto S, Thiene G, Corrado D. Nonischemic Left Ventricular Scar as a Substrate of Life-Threatening Ventricular Arrhythmias and Sudden Cardiac Death in Competitive Athletes. Circ Arrhythm Electrophysiol. 2016;9(7):e004229. doi: 10.1161/CIRCEP.116.004229.

67. Maron BJ, Pelliccia A, Spirito P. Cardiac disease in young trained athletes. Insights into methods for distinguishing athlete's heart from structural heart disease with particular emphasis on hypertrophic cardiomyopathy. Circulation. 1995;91:1596–1601.

68. Rowin EJ, Maron BJ, Chokshi A, Kannappan M, Arkun K, Wang W, Rastegar H, Maron MS. Clinical Spectrum and Management Implications of Left Ventricular Outflow Obstruction With Mild Ventricular Septal Thickness in Hypertrophic Cardiomyopathy. Am J Cardiol. 2018;122(8):1409-1420. doi: 10.1016/j.amjcard.2018.06.055

Journal Pre-proof

69. Mandeş L, Roşca M, Ciupercă D, Popescu BA. The role of echocardiography for diagnosis and prognostic stratification in hypertrophic cardiomyopathy. J Echocardiogr. 2020;18(3):137-148. doi: 10.1007/s12574-020-00467-9

70. Christiaans I, van Engelen K, van Langen IM, Birnie E, Bonsel GJ, Elliott PM, Wilde AA. Risk stratification for sudden cardiac death in hypertrophic cardiomyopathy: systematic review of clinical risk markers. Europace. 2010;12(3):313-21. doi: 10.1093/europace/eup431

71. Elliott PM, Anastasakis A, Borger MA, Borggrefe M, Cecchi F, Charron P, Hagege AA, Lafont A, Limongelli G, Mahrholdt H, McKenna WJ, Mogensen J, Nihoyannopoulos P, Nistri S, Pieper PG, Pieske B, Rapezzi C, Rutten FH, Tillmanns C, Watkins H. 2014 ESC Guidelines on diagnosis and management of hypertrophic cardiomyopathy: the Task Force for the Diagnosis and Management of Hypertrophic Cardiomyopathy of the European Society of Cardiology (ESC). Eur Heart J. 2014;35(39):2733-79. doi: 10.1093/eurheartj/ehu284.

72. O'Mahony C, Jichi F, Pavlou M, Monserrat L, Anastasakis A, Rapezzi C, Biagini E, Gimeno JR, Limongelli G, McKenna WJ, Omar RZ, Elliott PM. A novel clinical risk prediction model for sudden cardiac death in hypertrophic cardiomyopathy (HCM Risk-SCD). Eur Heart J 2014;35:2010–2020

73. Millar LM, Fanton Z, Finocchiaro G, Sanchez-Fernandez G, Dhutia H, Malhotra A, Merghani A, Papadakis M, Behr ER, Bunce N, Oxborough D, Reed M, O'Driscoll J, Tome Esteban MT, D'Silva A, Carr-White G, Webb J, Sharma R, Sharma S. Differentiation between athlete's heart and dilated cardiomyopathy in athletic individuals. Heart. 2020;106(14):1059-1065. doi: 10.1136/

74. Abergel E, Chatellier G, Hagege AA, Oblak A, Linhart A, Ducardonnet A, Menard J. Serial left ventricular adaptations in world-class professional cyclists: implications for disease screening and follow-up. J Am Coll Cardiol. 2004;44(1):144-9. doi: 10.1016/j.jacc.2004.02.057

75. Mathew T, Williams L, Navaratnam G, Rana B, Wheeler R, Collins K, Harkness A, Jones R, Knight D, O'Gallagher K, Oxborough D, Ring L, Sandoval J, Stout M, Sharma V, Steeds RP; British Society of Echocardiography Education Committee. Diagnosis and assessment of dilated cardiomyopathy: a guideline protocol from the British Society of Echocardiography. Echo Res Pract. 2017;4(2):G1-G13. doi: 10.1530/ERP-16-0037.

76. Tayal U, Newsome S, Buchan R, Whiffin N, Halliday B, Lota A, Roberts A, Baksi AJ, Voges I, Midwinter W, Wilk A, Govind R, Walsh R, Daubeney P, Jarman JWE, Baruah R, Frenneaux M, Barton PJ, Pennell D, Ware JS, Prasad SK, Cook SA. Phenotype and Clinical Outcomes of Titin Cardiomyopathy. J Am Coll Cardiol. 2017;70(18):2264-2274. doi: 10.1016/j.jacc.2017.08.063.

77. Małek ŁA, Mazurkiewicz Ł, Marszałek M, Barczuk-Falęcka M, Simon JE, Grzybowski J, Miłosz-Wieczorek B, Postuła M, Marczak M. Deformation Parameters of the Heart in Endurance Athletes and in Patients with Dilated Cardiomyopathy-A Cardiac Magnetic Resonance Study. Diagnostics (Basel). 2021;11(2):374. doi: 10.3390/diagnostics11020374

78. Claessen G, De Bosscher R, Janssens K, Young P, Dausin C, Claeys M, Claus P, Goetschalckx K, Bogaert J, Mitchell AM, Flannery MD, Elliott AD, Yu C, Ghekiere O, Robyns T, Van De Heyning CM, Sanders P, Kalman JM, Ohanian M, Soka M, Rath E, Giannoulatou E, Johnson R, Lacaze P, Herbots L, Willems R, Fatkin D, Heidbuchel H, La Gerche A; Pro@Heart Consortium. Reduced Ejection Fraction in Elite Endurance Athletes: Clinical and Genetic Overlap With Dilated Cardiomyopathy. Circulation. 2023 . doi: 10.1161/CIRCULATIONAHA.122.063777.

79. Tadros R, Francis C, Xu X, Vermeer AMC, Harper AR, Huurman R, Kelu Bisabu K, Walsh R, Hoorntje ET, Te Rijdt WP, Buchan RJ, van Velzen HG, van Slegtenhorst MA, Vermeulen JM, Offerhaus JA, Bai W, de Marvao A, Lahrouchi N, Beekman L, Karper JC, Veldink JH, Kayvanpour E, Pantazis A, Baksi AJ, Whiffin N, Mazzarotto F, Sloane G, Suzuki H, Schneider-Luftman D, Elliott P, Richard P, Ader F, Villard E, Lichtner P, Meitinger T, Tanck MWT, van Tintelen JP, Thain A, McCarty D, Hegele RA, Roberts JD,

Journal Pre-proof

Amyot J, Dubé MP, Cadrin-Tourigny J, Giraldeau G, L'Allier PL, Garceau P, Tardif JC, Boekholdt SM, Lumbers RT, Asselbergs FW, Barton PJR, Cook SA, Prasad SK, O'Regan DP, van der Velden J, Verweij KJH, Talajic M, Lettre G, Pinto YM, Meder B, Charron P, de Boer RA, Christiaans I, Michels M, Wilde AAM, Watkins H, Matthews PM, Ware JS, Bezzina CR. Shared genetic pathways contribute to risk of hypertrophic and dilated cardiomyopathies with opposite directions of effect. Nat Genet. 2021;53(2):128-134. doi: 10.1038/s41588-020-00762-2.

80. Arbelo E, Protonotarios A, Gimeno JR, Arbustini E, Barriales-Villa R, Basso C, Bezzina CR, Biagini E, Blom NA, de Boer RA, De Winter T, Elliott PM, Flather M, Garcia-Pavia P, Haugaa KH, Ingles J, Jurcut RO, Klaassen S, Limongelli G, Loeys B, Mogensen J, Olivotto I, Pantazis A, Sharma S, Van Tintelen JP, Ware JS, Kaski JP; ESC Scientific Document Group. 2023 ESC Guidelines for the management of cardiomyopathies. Eur Heart J. 2023;44(37):3503-3626. doi: 10.1093/eurheartj/ehad194. PMID: 3762265

81. McDonagh TA, Metra M, Adamo M, Gardner RS, Baumbach A, Böhm M, Burri H, Butler J, Čelutkienė J, Chioncel O, Cleland JGF, Coats AJS, Crespo-Leiro MG, Farmakis D, Gilard M, Heymans S, Hoes AW, Jaarsma T, Jankowska EA, Lainscak M, Lam CSP, Lyon AR, McMurray JJV, Mebazaa A, Mindham R, Muneretto C, Francesco Piepoli M, Price S, Rosano GMC, Ruschitzka F, Kathrine Skibelund A; ESC Scientific Document Group. 2021 ESC Guidelines for the diagnosis and treatment of acute and chronic heart failure. Eur Heart J. 2021;42(36):3599-3726. doi: 10.1093/eurheartj/ehab368

82. Heidenreich PA, Bozkurt B, Aguilar D, Allen LA, Byun JJ, Colvin MM, Deswal A, Drazner MH, Dunlay SM, Evers LR, Fang JC, Fedson SE, Fonarow GC, Hayek SS, Hernandez AF, Khazanie P, Kittleson MM, Lee CS, Link MS, Milano CA, Nnacheta LC, Sandhu AT, Stevenson LW, Vardeny O, Vest AR, Yancy CW. 2022 AHA/ACC/HFSA Guideline for the Management of Heart Failure: A Report of the American College of Cardiology/American Heart Association Joint Committee on Clinical Practice Guidelines. Circulation. 2022;145(18):e895-e1032. doi: 10.1161/CIR.0000000000001063.

83. Njoroge JN, Teerlink JR. Pathophysiology and Therapeutic Approaches to Acute Decompensated Heart Failure. Circ Res. 2021;128(10):1468-1486. doi: 10.1161/CIRCRESAHA.121.318186.

84. Alba AC, Foroutan F, Duero Posada J, Battioni L, Schofield T, Alhussein M, Agoritsas T, Spencer FA, Guyatt G. Implantable cardiac defibrillator and mortality in non-ischaemic cardiomyopathy: an updated meta-analysis. Heart. 2018;104(3):230-236. doi: 10.1136/heartjnl-2017-311430

85. Corrado D, Link MS, Calkins H. Arrhythmogenic Right Ventricular Cardiomyopathy. N Engl J Med. 2017;376(1):61-72. doi: ACM10.1056/NEJM1509267

86. de la Guía-Galipienso F, Ugedo-Alzaga K, Grazioli G, Quesada-Ocete FJ, Feliu-Rey E, Perez MV, Quesada-Dorador A, Sanchis-Gomar F. Arrhythmogenic Cardiomyopathy and Athletes: A Dangerous Relationship. Curr Probl Cardiol. 2023;48(9):101799. doi: 10.1016/j.cpcardiol.2023.101799.

87. James CA, Syrris P, van Tintelen JP, Calkins H. The role of genetics in cardiovascular disease: arrhythmogenic cardiomyopathy. Eur Heart J. 2020;41(14):1393-1400. doi: 10.1093/eurheartj/ehaa141

88. James CA, Syrris P, van Tintelen JP, Calkins H. The role of genetics in cardiovascular disease: arrhythmogenic cardiomyopathy. Eur Heart J. 2020;41:1393–1400;

89. Gandjbakhch E, Redheuil A, Pousset F, Charron P, Frank R. Clinical diagnosis, imaging, and genetics of arrhythmogenic right ventricular cardiomyopathy/dysplasia: JACC state-of-the-art review. J Am Coll Cardiol. 2018;72:784–804.

90. Calkins H, Corrado D, Marcus F. Risk Stratification in Arrhythmogenic Right Ventricular Cardiomyopathy. Circulation. 2017;136(21):2068-2082. doi: 10.1161/CIRCULATIONAHA.117.030792.

91. Krahn AD, Wilde AAM, Calkins H, La Gerche A, Cadrin-Tourigny J, Roberts JD, Han HC. Arrhythmogenic Right Ventricular Cardiomyopathy. JACC Clin Electrophysiol. 2022;8(4):533-553. doi: 10.1016/j.jacep.2021.12.002.

Journal Pre-proof

92. Gupta R, Tichnell C, Murray B, Rizzo S, Te Riele A, Tandri H, Judge DP, Thiene G, Basso C, Calkins H, James CA. Comparison of Features of Fatal Versus Nonfatal Cardiac Arrest in Patients With Arrhythmogenic Right Ventricular Dysplasia/Cardiomyopathy. Am J Cardiol. 2017 1;120(1):111-117. doi: 10.1016/j.amjcard.2017.03.251.

93. Marcus FI, McKenna WJ, Sherrill D, Basso C, Bauce B, Bluemke DA, Calkins H, Corrado D, Cox MG, Daubert JP, Fontaine G, Gear K, Hauer R, Nava A, Picard MH, Protonotarios N, Saffitz JE, Sanborn DM, Steinberg JS, Tandri H, Thiene G, Towbin JA, Tsatsopoulou A, Wichter T, Zareba W. Diagnosis of arrhythmogenic right ventricular cardiomyopathy/dysplasia: proposed modification of the Task Force Criteria. Eur Heart J. 2010;31(7):806-14. doi: 10.1093/eurheartj/ehq025.

94 Towbin JA, McKenna WJ, Abrams DJ, Ackerman MJ, Calkins H, Darrieux FCC, Daubert JP, de Chillou C, DePasquale EC, Desai MY, Estes NAM 3rd, Hua W, Indik JH, Ingles J, James CA, John RM, Judge DP, Keegan R, Krahn AD, Link MS, Marcus FI, McLeod CJ, Mestroni L, Priori SG, Saffitz JE, Sanatani S, Shimizu W, van Tintelen JP, Wilde AAM, Zareba W. 2019 HRS expert consensus statement on evaluation, risk stratification, and management of arrhythmogenic cardiomyopathy. Heart Rhythm. 2019;16(11):e301-e372. doi: 10.1016/j.hrthm.2019.05.007.

95. Perrin MJ, Angaran P, Laksman Z, Zhang H, Porepa LF, Rutberg J, James C, Krahn AD, Judge DP, Calkins H, Gollob MH. Exercise testing in asymptomatic gene carriers exposes a latent electrical substrate of arrhythmogenic right ventricular cardiomyopathy. J Am Coll Cardiol. 2013;62(19):1772-9. doi: 10.1016/j.jacc.2013.04.084.

96. Cadrin-Tourigny J, Bosman LP, Nozza A, Wang W, Tadros R, Bhonsale A, Bourfiss M, Fortier A, Lie ØH, Saguner AM, Svensson A, Andorin A, Tichnell C, Murray B, Zeppenfeld K, van den Berg MP, Asselbergs FW, Wilde AAM, Krahn AD, Talajic M, Rivard L, Chelko S, Zimmerman SL, Kamel IR, Crosson JE, Judge DP, Yap SC, van der Heijden JF, Tandri H, Jongbloed JDH, Guertin MC, van Tintelen JP, Platonov PG, Duru F, Haugaa KH, Khairy P, Hauer RNW, Calkins H, Te Riele ASJM, James CA. A new prediction model for ventricular arrhythmias in arrhythmogenic right ventricular cardiomyopathy. Eur Heart J. 2019;40(23):1850-1858. doi: 10.1093/eurheartj/ehz103. Erratum in: Eur Heart J. 2022;43(28):2712.

97. Aquaro GD, De Luca A, Cappelletto C, et al. Comparison of different prediction models for the indication of implanted cardioverter defibrillator in patients with arrhythmogenic right ventricular cardiomyopathy. ESC Heart Fail 2020;7:4080–4088.doi.org/10.1002/ehf2.13019.

98. Gasperetti A, Dello Russo A, Busana M, Dessanai M, Pizzamiglio F, Saguner AM, Te Riele ASJM, Sommariva E, Vettor G, Bosman L, Duru F, Zeppilli P, Di Biase L, Natale A, Tondo C, Casella M. Novel risk calculator performance in athletes with arrhythmogenic right ventricular cardiomyopathy. Heart Rhythm. 2020;17(8):1251-1259. doi: 10.1016/j.hrthm.2020.03.007.

99. Corrado D, Wichter T, Link MS, Hauer RN, Marchlinski FE, Anastasakis A, Bauce B, Basso C, Brunckhorst C, Tsatsopoulou A, Tandri H, Paul M, Schmied C, Pelliccia A, Duru F, Protonotarios N, Estes NM 3rd, McKenna WJ, Thiene G, Marcus FI, Calkins H. Treatment of Arrhythmogenic Right Ventricular Cardiomyopathy/Dysplasia: An International Task Force Consensus Statement. Circulation. 2015;132(5):441-53. doi: 10.1161/CIRCULATIONAHA.115.017944.

100. Wang W, Orgeron G, Tichnell C, Murray B, Crosson J, Monfredi O, Cadrin-Tourigny J, Tandri H, Calkins H, James CA. Impact of Exercise Restriction on Arrhythmic Risk Among Patients With Arrhythmogenic Right Ventricular Cardiomyopathy. J Am Heart Assoc. 2018;7(12):e008843. doi: 10.1161/JAHA.118.008843. P

101. Lie ØH, Dejgaard LA, Saberniak J, Rootwelt C, Stokke MK, Edvardsen T, Haugaa KH. Harmful Effects of Exercise Intensity and Exercise Duration in Patients With Arrhythmogenic Cardiomyopathy. JACC Clin Electrophysiol. 2018;4(6):744-753. doi: 10.1016/j.jacep.2018.01.010.

102. Wang W, Tichnell C, Murray BA, Agafonova J, Cadrin-Tourigny J, Chelko S, Tandri H, Calkins H, James CA. Exercise restriction is protective for genotype-positive family members of arrhythmogenic right ventricular cardiomyopathy patients. Europace. 2020;22(8):1270-1278. doi: 10.1093/europace/euaa10

Journal Pre-proof

103. Sawant AC, Te Riele AS, Tichnell C, Murray B, Bhonsale A, Tandri H, Judge DP, Calkins H, James CA. Safety of American Heart Association-recommended minimum exercise for desmosomal mutation carriers. Heart Rhythm. 2016;13(1):199-207. doi: 10.1016/j.hrthm.2015.08.035.

104. Ermakov S, Gerstenfeld EP, Svetlichnaya Y, Scheinman MM. Use of flecainide in combination antiarrhythmic therapy in patients with arrhythmogenic right ventricular cardiomyopathy. Heart Rhythm. 2017;14:564–569.

105. Liang E, Wu L, Fan S, Hu F, Zheng L, Liu S, Fan X, Chen G, Ding L, Niu G, Yao Y. Catheter ablation of arrhythmogenic right ventricular cardiomyopathy ventricular tachycardia: 18-year experience in 284 patients. Europace. 2020;22(5):806-812. doi: 10.1093/europace/euaa046.

106. Mahida S, Venlet J, Saguner AM, Kumar S, Baldinger SH, AbdelWahab A, Tedrow UB, Castelletti S, Pantazis A, John RM, McKenna WJ, Lambiase PD, Duru F, Sapp JL, Zeppenfeld K, Stevenson WG. Ablation compared with drug therapy for recurrent ventricular tachycardia in arrhythmogenic right ventricular cardiomyopathy: Results from a multicenter study. Heart Rhythm. 2019;16(4):536-543. doi: 10.1016/j.hrthm.2018.10.016.

107. Olde Nordkamp LR, Postema PG, Knops RE, van Dijk N, Limpens J, Wilde AA, de Groot JR. Implantable cardioverter-defibrillator hACM in young patients with inherited arrhythmia syndromes: A systematic review and meta-analysis of inappropriate shocks and complications. Heart Rhythm. 2016;13(2):443-54. doi: 10.1016/j.hrthm.2015.09.010.

108. Corrado D, Leoni L, Link MS, Della Bella P, Gaita F, Curnis A, Salerno JU, Igidbashian D, Raviele A, Disertori M, Zanotto G, Verlato R, Vergara G, Delise P, Turrini P, Basso C, Naccarella F, Maddalena F, Estes NA III, Buja G, Thiene G. Implantable cardioverter-defibrillator therapy for prevention of sudden death in patients with arrhythmogenic right ventricular cardiomyopathy/dysplasia. Circulation 2003; 108:3084–3091.

109. Wichter T, Paul M, Wollmann C, Acil T, Gerdes P, Ashraf O, Tjan TD, Soeparwata R, Block M, Borggrefe M, Scheld HH, Breithardt G, Bocker D. Implantable cardioverter/defibrillator therapy in arrhythmogenic right ventricular cardiomyopathy: single-center experience of long-term follow-up and complications in 60 patients. Circulation 2004;109:1503–1508.

110. Tedford RJ, James C, Judge DP, Tichnell C, Murray B, Bhonsale A, Philips B, Abraham T, Dalal D, Halushka MK, Tandri H, Calkins H, Russell SD. Cardiac transplantation in arrhythmogenic right ventricular dysplasia/cardiomyopathy. J Am Coll Cardiol 2012;59:289–290.

111. Saarel E, Pilcher T, Gamboa D, Etheridge S. Sports for young patients with implantable cardioverter-defibrillators: refining the risk. J Am Coll Cardiol. 2014;63(12s):A529.

112. Saarel EV, Pilcher TA, Etheridge SP. Safety of sports for pediatric and congenital ICD and pacemaker patients. Heart Rhythm. 2013;10(5S):211

113. Lampert R, Olshansky B, Heidbuchel H, Lawless C, Saarel E, Ackerman M, Calkins H, Estes NA, Link MS, Maron BJ, Marcus F, Scheinman M, Wilkoff BL, Zipes DP, Berul CI, Cheng A, Law I, Loomis M, Barth C, Brandt C, Dziura J, Li F, Cannom D. Safety of sports for athletes with implantable cardioverter-defibrillators: results of a prospective, multinational registry. Circulation. 2013;127:2021–2030. doi: 10.1161/CIRCULATIONAHA.112.000447

114. Lampert R, Olshansky B, Heidbuchel H, Lawless C, Saarel E, Ackerman M, Calkins H, Estes NAM, Link MS, Maron BJ, Marcus F, Scheinman M, Wilkoff BL, Zipes DP, Berul CI, Cheng A, Jordaens L, Law I, Loomis M, Willems R, Barth C, Broos K, Brandt C, Dziura J, Li F, Simone L, Vandenberghe K, Cannom D. Safety of sports for athletes with implantable cardioverter-defibrillators: long-term results of a prospective multinational registry. Circulation. 2017;135:2310–2312. doi: 10.1161/CIRCULATIONAHA.117.027828 10.

115. Saarel E, Pilcher T, Gamboa D, Etheridge S. Sports for young; Saarel EV, Law I, Berul CI, Ackerman MJ, Kanter RJ, Sanatani S, Cohen MI, Berger S, Fischbach PS, Burton DA, Dziura J, Brandt C, Simone L, Li F, Olshansky B, Cannom DS, Lampert RJ. Safety of Sports for Young Patients With

Journal Pre-proof

Implantable Cardioverter-Defibrillators: Long-Term Results of the Multinational ICD Sports Registry. Circ Arrhythm Electrophysiol. 2018;11(11):e006305. doi: 10.1161/CIRCEP.118.006305.

116. Heidbuchel H, Willems R, Jordaens L, Olshansky B, Carre F, Lozano IF, Wilhelm M, Müssigbrodt A, Huybrechts W, Morgan J, Anfinsen OG, Prior D, Mont L, Mairesse GH, Boveda S, Duru F, Kautzner J, Viskin S, Geelen P, Cygankiewicz I, Hoffmann E, Vandenberghe K, Cannom D, Lampert R. Intensive recreational athletes in the prospective multinational ICD Sports Safety Registry: Results from the European cohort. Eur J Prev Cardiol. 2019 May;26(7):764-775. doi: 10.1177/2047487319834852.

117. Zipes DP, Link MS, Ackerman MJ, Kovacs RJ, Myerburg RJ, Estes NA 3rd; American Heart Association Electrocardiography and Arrhythmias Committee of Council on Clinical Cardiology, Council on Cardiovascular Disease in Young, Council on Cardiovascular and Stroke Nursing, Council on Functional Genomics and Translational Biology, and American College of Cardiology. Eligibility and disqualification recommendations for competitive athletes with cardiovascular abnormalities: Task Force 9: arrhythmias and conduction defects: a scientific statement from the American Heart Association and American College of Cardiology. Circulation 2015;132:e315–e325;.

118. Lampert R, Zipes DP. Updated recommendations for athletes with heart disease. Annu Rev Med 2018;69:177–189.

119. Heidbuchel H, Arbelo E, D'Ascenzi F, Borjesson M, Boveda S, Castelletti S, Miljoen H, Mont L, Niebauer J, Papadakis M, Pelliccia A, Saenen J, Sanz de la Garza M, Schwartz PJ, Sharma S, Zeppenfeld K, Corrado D; EAPC/EHRA update of the Recommendations for participation in leisure-time physical activity and competitive sports in patients with arrhythmias and potentially arrhythmogenic conditions. Recommendations for participation in leisure-time physical activity and competitive sports of patients with arrhythmias and potentially arrhythmogenic conditions. Part 2: ventricular arrhythmias, channelopathies, and implantable defibrillators. Europace. 2021;23(1):147-148. doi: 10.1093/europace/euaa106. Erratum in: Europace. 2021;23(7):1113.

120. Naeem M, Aziz P. Latest in Cardiology: Practical Considerations For ICD in Athletes. JACC November, 2022. https://www.acc.org/Latest-in-Cardiology/Articles/2022/11/30/12/56/Practical-Considerations-For-ICD-in-Athletes

121. Olshansky B, Atteya G, Cannom D, Heidbuchel H, Saarel EV, Anfinsen OG, Cheng A, Gold MR, Müssigbrodt A, Patton KK, Saxon LA, Wilkoff BL, Willems R, Dziura J, Li F, Brandt C, Simone L, Wilhelm M, Lampert R. Competitive athletes with implantable cardioverter-defibrillators-How to program? Data from the Implantable Cardioverter-Defibrillator Sports Registry. Heart Rhythm. 2019 Apr;16(4):581-587. doi: 10.1016/j.hrthm.2018.10.032.

122 Hainline B, Drezner J, Baggish A, Harmon KG, Emery MS, Myerburg RJ, Sanchez E, Molossi S, Parsons JT, Thompson PD. Interassociation Consensus Statement on Cardiovascular Care of College Student-Athletes. J Athl Train. 2016;51(4):344-57. doi: 10.4085/j.jacc.2016.03.527.

123. Passman R, Subacius H, Ruo B, Schaechter A, Howard A, Sears SF, Kadish A. Implantable cardioverter defibrillators and quality of life: results from the defibrillators in nonischemic cardiomyopathy treatment evaluation study. Arch Intern Med 2007;167:2226–2232.

124. Dunbar SB, Dougherty CM, Sears SF, Carroll DL, Goldstein NE, Mark DB, McDaniel G, Pressler SJ, Schron E, Wang P, Zeigler VL. American Heart Association Council on Cardiovascular Nursing, Council on Clinical Cardiology, and Council on Cardiovascular Disease in the Young. Educational and psychological interventions to improve outcomes for recipients of implantable cardioverter defibrillators and their families: a scientific statement from the American Heart Association. Circulation 2012;126:2146–2172

Journal Pre-proof